


<https://doi.org/10.48047/AFJBS.6.8.2024.392-401>



## African Journal of Biological Sciences



Research Paper

Open Access

### "Morphometric Analysis of the Femoral Head in the Population of Madhya Pradesh"

**First author/ Corresponding author Details:**

**Dr.Mohd Zaid Khan**

PhD Scholar, Index Medical College Hospital and Research Center, Malwanchal University  
Indore Madhya Pradesh

Email Id: [zaidrajputana@gmail.com](mailto:zaidrajputana@gmail.com)

Phone number: 8433109502

**Second author details:**

**DR AVANTIKA BAMNE**

PROF,department of Anatomy Krishna institute of medical sciences,karad,Maharashtra-415539.

#### Article History

Volume 6, Issue 8, 2024

Received: 15 Mar 2024

Accepted : 17 Apr 2024

doi: 10.33472/AFJBS.6.8.2024.392-401

#### Abstract

**Introduction:** Orthopedic procedures involving the proximal end of the femur are commonplace in medical practice. Understanding the morphometry of the femur can mitigate potential complications associated with procedures related to vascular, metabolic, or trauma-induced conditions. The current study aims to gather data on femur morphometric values to enhance implant design suitability for the specific needs of the population in Madhya Pradesh, thereby reducing potential issues.

**Objectives:** The objectives of this study are to examine various measurements of the femur and compare these findings with previous research.

**Materials and Methods:** Ninety dried femurs were sourced from the Department of Anatomy at [Institution's Name]. Measurements, including head transverse diameter and head vertical diameter, were conducted utilizing vernier calipers, goniometers, and osteometric boards.

**Findings:** The head transverse diameter (left side femur) measured  $41.9 \pm 2.8$  mm, while the head transverse diameter (right side femur) measured  $44.0 \pm 3.3$  mm in dried femora. The head vertical diameter (left side femur) measured  $29.0 \pm 3.48$  mm, and the femoral head vertical diameter (right side femur) measured  $29.0 \pm 3.42$  mm.

**Conclusion:** This study highlights notable differences in femur measurements within the Madhya Pradesh population compared to other populations. Such insights can significantly impact the diagnostic and treatment planning processes of radiologists and orthopedic surgeons, as well as inform anthropological and medico-legal practices.

**Keywords:** Femur, morphometry, femur head, diameter, vertical.

## INTRODUCTION

The femur, being the longest and most robust bone within the human anatomy, holds significant importance across various fields such as forensic science, orthopedic surgery, sports medicine, and anatomy. Its robustness correlates directly with body mass and the forces it withstands. Structurally, the femur consists of a shaft, distal end, and proximal end, featuring prominent projections like the greater and lesser trochanters. Articulating with the fovea for ligament attachment. Osteoporosis, characterized by decreased bone mineral density, commonly affects the proximal femur, posing fracture risks despite normal mineral density in some cases. Fractures at the proximal end necessitate internal fixation for early patient mobilization, with implants tailored to femur measurements, a demand especially noted among Indian orthopedic practitioners. Measurement techniques include mechanical means for cadaveric bones and various imaging methods for patients. Pre-operative assessment, particularly for cemented arthroplasty, benefits from combining computed tomography and radiography. Anthropometry aids in assessing body part dimensions across different populations, revealing variances like medium femur size in central India compared to other regions.

Mismatch between the proximal femur geometry of the Indian population and commercially available hip joint prostheses, often designed with Caucasian and Chinese specifications, leads to complications like loosening and pain. Population-specific data are crucial for designing implants tailored to Indian anatomical needs, aiming to mitigate issues such as incorrect load distribution and stress shielding. This study aims to measure proximal femur bony indices for creating tailor-made implants and prostheses tailored to the demographic characteristics of the Madhya Pradesh region.

## Materials and Method

### Collection of the specimen:

One hundred adult human dry femora of undetermined gender were sourced from the anatomy department of \_\_\_\_\_ College. Goniometers were utilized to measure the neck-shaft angle, while femoral head and neck circumferences were assessed with a tape measure. Vernier calipers were employed to measure various parameters:

**Femoral Head Diameter:** This measurement involved determining the maximal diameter of the femoral head from its posterosuperior to anteroinferior aspects.

**Transverse Diameter:** The sliding caliper was employed to ascertain the greatest width of the head in the horizontal plane.

**Vertical Diameter:** Similarly, the sliding caliper was utilized to determine the largest measurement of the head along the vertical axis.

Moreover, a sliding caliper was utilized to determine the widest distance between the femur head and the greater trochanter, while the diameter of the head was calculated by measuring the straight-line distance between its upper and lower extremities along the cranio-caudal axis. Afterward, all collected data underwent organization, tabulation, and comprehensive scrutiny. Descriptive analyses were carried out using the Statistical Package for Social Sciences (SPSS) software for statistical examination.

### Result

Ninety dry femora sourced from the Anatomy Department of [College Name], were selected for femoral measurement analysis. These femora originated from cadavers submitted for medicolegal autopsy procedures at the department. Excluded from the study were any femora exhibiting fractures or damage. Digital Vernier calipers were employed for precise measurements, while an analog goniometer was utilized to determine the neck shaft angle. Significance assessment involved subjecting the measurements from both left and right sides to thorough statistical analysis.

Top of Form

**Table 1: Transverse Diameter of the Femur Head (LSF):**

Statistical data	Transverse Diameter of the Femoral Head in Dry Femora (LSF)
Number of sample	45
Smallest diameter	35.6
Highest diameter	48.3
Mean diameter	41.9
S.D	2.8


Table 1 displays information regarding the horizontal width of the femoral head (LSF) in dry femora. Following examination, it was established that the mean head diameter in dry femurs is 41.9. This discovery offers significant understanding into the physical attributes of femoral bone composition.

**Table 2: Transverse Diameter of the Femur head (RSF)**

Statistical data	Femur transverse diameter of head
Number of sample	45
Smallest diameter	35.6
Highest diameter	48.3
Mean diameter	44.0
S.D	3.3

Table 3 showcases information concerning the horizontal width of the femoral head (RSF) in dry femora. Through analysis, it was ascertained that the mean head diameter in dry femurs is 44.0. This discovery offers valuable understanding regarding the physical traits of femoral bone structure.

Top of Form

**Graph: Femoral transverse diameter of head in dry femora****Table 3: Vertical Diameter of the Head (LSF)**

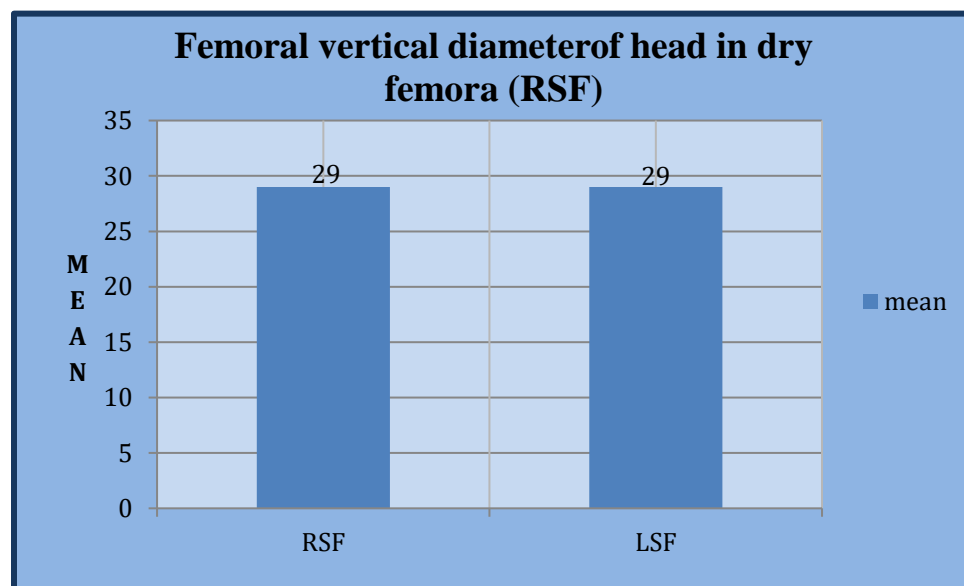
Statistical data	Femur vertical diameter of head diameter
Number of sample	43
Smallest diameter	20.8
Largest diameter	34.6
Mean diameter	29.0
S.D	3.48

Table 3 presents data on the height measurement of the femoral head (LSF) in dried femur samples. After extensive analysis, It was determined that the mean size of the femoral head in these dehydrated femurs is 29.0. This discovery offers valuable insights into the structural traits of femoral bones.

**Table 5: Vertical Diameter of the Head in Dry Femora (RSF)**

Statistical data	Vertical Diameter of the Femur Head (RSF)
Number of femora	45
Smallest diameter	22.2
Highest diameter	35.2
Mean diameter	29.0
S.D	3.42

Table 5 displays data pertaining to the height of the femoral head (RSF) in dehydrated femur samples. After meticulous analysis, it was established that the mean size of the femoral head within these desiccated femurs is 29.0. This finding yields vital insights into the structural attributes of femoral bones.



**Graph: Femoral vertical diameter of head in dry femora (RSF)**

**Statistical Analysis:** All data were collected, compiled, and subjected to thorough examination. Statistical analysis for descriptive purposes was performed using the Statistical Package for Social Sciences (SPSS) software.

## Discussion

Understanding the anatomical variations of the femur is instrumental in diagnosing and treating proximal femur disorders. Osteoporosis, predominantly affecting the elderly, often leads to proximal femur fractures (Maffulli and Aicale, 2022), necessitating surgical intervention as the primary treatment modality. In recent years, there has been a notable surge in total hip arthroplasties and hip revision procedures performed globally (Singh, 2011), ranging from arthroplasty to fracture osteosynthesis using various techniques such as plates, screws, and intramedullary nails. The paramount objective of treatment remains the restoration of normal anatomy (Alsheikh et al., 2022).

Projected studies suggest a substantial 174% increase in demand for primary complete hip arthroplasties by 2023 (Cieremans et al., 2023). Over the past decade, India has witnessed a remarkable rise in joint replacement surgeries, conducting between 1000 and 2500 total hip arthroplasties from 2006 to 2019 (Cieremans et al., 2023).

Anthropometric assessments of the upper femur can be instrumental in crafting well-suited and personalized femoral implants and prostheses, ultimately improving treatment results amidst the increasing prevalence of hip surgeries (Bounti et al., 2017).

Numerous investigations into femur morphometry have been conducted across various locations. These studies utilized a range of tools and methodologies, including cadaveric specimens, dry bones, and plain radiographs, to explore diverse femur properties. Our research underscores the significance of incorporating regional variations in vertical head diameters for comprehensive hip substitution procedures. In our study, we found the vertical diameter of the head to be  $29.0 \pm 3.48$ . Research conducted in southern India by Lingamdenne et al., Kamath et al., and Sengodan et al. revealed mean head diameters of  $42.3 \pm 0.54$  mm,  $44.8 \pm 4.2$  mm, and  $42.6 \pm 4.4$  mm, respectively (Lingamdenne et al., 2016; Kamath et al., 2020).

Similarly research in northern India by Siwach and Verma indicated mean head diameters of  $43.95 \pm 3.06$  mm and  $42.32 \pm 4.11$  mm, respectively (Verma et al., 2017). Javadekar et al. noted femoral head diameters of 40.37 mm for females and 45.26 mm for males (Javadekar et al., 1961), while Kate (1964) reported an average diameter of 41.50 mm (Kate, 1967). Isaac et al. found femoral head diameters of 43 mm for males and 39.1 mm for females (Isaac et al., 1997), while Chauhan et al. observed vertical diameters of 45.44 mm for men and 43.87 mm for women (Chauhan et al., 2002). Pandya et al. reported mean values of 43.75 mm and 43.88 mm for males

on the right and left sides, respectively, and 40.33 mm and 40.64 mm for females (Pandya et al., 2012). CT scans conducted by Rawal et al. revealed a mean femoral head diameter of 45.41 mm (Rawal et al., 2012), while Deswal et al. found values of 45.96 mm for males and 41.17 mm for females (Deswal et al., 2017). Jayashree et al. reported diameters of 44 mm and 45.53 mm for males on the right and left sides, respectively, and 41.12 mm and 41.0 mm for females (Jayashree et al., 2013). Roy et al. noted diameters of 4.45 cm in females and 4.6 cm in males (Roy et al., 2014), and Tumusiime et al. found mean diameters of 44.08 $\pm$ 3.39 mm in X-ray films and 39.62 $\pm$ 3.06 mm in CT images (Tumusiime et al., 2021), which aligned with our study's findings. Determining the precise femoral head diameter is crucial for orthopedic surgeons managing hip osteoarthritis and femur neck fractures to ensure proper implant fit and fixation and mitigate complications such as micromotion and intraoperative challenges associated with large implants. Moreover, understanding the genetic, environmental, geological, and racial influences on femoral head dimensions is essential, as these factors can impact mechanical stress on the femur.

Orthopedic specialists emphasize the critical importance of femoral neck length, as its shortening can hinder the effectiveness of surgical procedures, particularly in repairing neck fractures where cancellous screw threads may fail to pass through the fracture site, resulting in inadequate compression. Approximately twenty-seven percent of an individual's stature is influenced by femur length. In our study, the average femur length was 33.11 $\pm$ 3.91 cm, aligning with findings by Kulkarni and Verma who determined lengths of 41.84 $\pm$ 1.62 cm and 36.61 $\pm$ 2.66 cm, respectively (Kulkarni et al., 2020). However, this figure contrasts with the investigations by Isaac and Chandran., who reported 43.4 $\pm$ 2.7 cm and 44.9 cm, respectively (Chandran and Kumar, 2012). According to Robinson et al. (2010), the mean length of the femur neck-axis was 114.2 mm. In our investigation, we observed that the femoral neck-axis length in desiccated femora varied from 79.0 mm to 108.00 mm, with an average of 93.42 $\pm$ 6.16 mm. Meanwhile, in X-ray images, the femoral neck-axis length ranged from 75.00 mm to 101.00 mm, with a mean of 89.91 $\pm$  6.27 mm, as reported by Robinson et al. (Robinson et al., 2016), which corresponded with our findings. Among the various proximal femoral morphometric characteristics assessed, femur length exhibited the strongest association with the vertical diameter of the head, followed closely by neck width and diameter. This underscores the interconnectedness of femoral length and proximal femoral traits.

Isaac et al. noted a notable positive relationship between the neck shaft angle and neck length, as well as between the minimum femoral length and the length of the intertrochanteric apical axis, our investigation found no such relationships between neck shaft angle and other variables. These findings highlight the complex interplay of proximal femoral characteristics and underscore the importance of precise morphometric assessments in orthopedic interventions.

### **Conclusion**

Sexual dimorphism is evident in the circumferences of the femoral head and neck, which could have significant forensic implications. We envision that this data will prove invaluable in guiding surgical interventions and arthroplasty procedures involving the proximal femur. Additionally, it provides essential insights for biomechanical engineers tasked with designing implants tailored to population-specific measurements. Importantly, the observed differences in femur measurements between the right and left sides are not statistically significant. Understanding the morphometric characteristics of the proximal femur holds promise for improving the diagnosis and treatment of hip and femur-related ailments, serving as a valuable resource for both anthropologists and medico-legal professionals.

### **References**

- Maffulli N, Aicale R. Proximal Femoral Fractures in the Elderly: A Few Things to Know, and Some to Forget. *Medicina (Kaunas)*. 2022; 20;58(10):1314. doi: 10.3390/medicina58101314. PMID: 36295475; PMCID: PMC9612001.
- Singh.IB. *A textbook of Human Histology with colour atlas and practical guide*; 6th edition; NewDelhi; Jaypee Medical Publishers, 2011; pg-121.
- Alsheikh KA, Alhandi AA, Almutlaq MS, Alhumaid LA, Shaheen N. The Outcomes and Revision Rate of Total Hip Arthroplasty in a Single Tertiary Center: A Retrospective Study. *Cureus*. 2022; 13;14(8):e27981. doi: 10.7759/cureus.27981. PMID: 36120254; PMCID: PMC9468514.
- Cieremans D, Shah A, Slover J, Schwarzkopf R, Meftah M. Trends in Complications and Outcomes in Patients Aged 65 Years and Younger Undergoing Total Hip Arthroplasty: Data From the American Joint Replacement Registry. *J Am Acad Orthop Surg Glob Res Rev*. 2023 Mar 17;7(3):e22.00256. doi: 10.5435/JAAOSGlobal-D-22-00256. PMID: 36930818; PMCID: PMC10027031.



- Bonutti P, Khlopas A, Chughtai M, Cole C, Gwam C, Harwin S, Whited B, Omiyi D, Drumm J. Unusually high rate of early failure of tibial component in ATTUNE total knee arthroplasty system at implant-cement interface. *The Journal of Knee Surgery*. 2017 doi: 10.1055/s-0037-1603756.
- Lingamdenne PE, Marapaka P, Lingamdenne PE: Examination evaluation and statistical analysis of human femoral anthropometry in Hyderabad and Secunderabad regions, India. *Indian J Clin Anat Physiol*. 2016, 3:427-432. 10.5958/2394-2126.2016.00097.9
- Kamath SU, Agarwal S, Austine J: Morphology of proximal femur in South-West Coast of India . *Malays Orthop J*. 2020, 14:143-150. 10.5704/MOJ.2011.022
- Verma M, Joshi S, Tuli A, Raheja S, Jain P, Srivastava P. Morphometry of Proximal Femur in Indian Population. *J Clin Diagn Res*. 2017;11(2):AC01-AC04. doi: 10.7860/JCDR/2017/23955.9210. Epub 2017 Feb 1. PMID: 28384844; PMCID: PMC5376818.
- Javadekar, BS. A study of the measurement of the head of the femur with special reference to sex: A preliminary report. *J Anat Soc India*. 1961, 10: 25–27
- Kate BR. The angle of femoral neck in Indians. *Eastern Anthropologist*. 1967, 20:54–60.
- Isaac B, Vettivel S, Prasad R, Jeyaseelan L, Chandi G: Prediction of the femoral neck-shaft angle from the length of the femoral neck. *Clin Anat*. 1997, 10:318-323. 10.1002/(SICI)1098-2353(1997)10:53.0.CO;2-M
- Chauhan R, Paul S, Dhaon BK. Anatomical parameters of North Indian Hip Joints: Cadaveric study. *J Anat Soc India* 2002; 51: 39 42
- Siwach RC, Dahiya S. Anthropometric Study of proximal femur geometry and it's clinical application. *Indian J Orthop*. 2003;37:247–51.
- Pandya AM, Gupta BD, Singel TC, Patel A Study of Sexual Dimorphism of Femoral Head In Gujarat Region, *Journal of Indian Academy of Forensic Medicine*, Year : 2012, 34(1), 20-23.
- Rawal BR, Ribeiro R, Malhotra R, Bhatnagar N. Anthropometric measurements to design best fit femoral stem for Indian population. *Indian J Orthop*. 2012;46(1):46–53.
- Deswal A, Saxena AK, Bala A. Measurement of Collo-Diaphyseal Angle and Femoral Neck Anteversion Angle of Femur Bone. *Int J Sci Stud*. 2017;5(1):97-99

- Jayashree, R., Malini, A., Rakhshani, A., Nagendra, H., Gunasheela, S., et al. (2013) Effect of the Integrated Approach of Yoga Therapy on Platelet Count and Uric Acid in Pregnancy: A Multicenter Stratified Randomized Single-Blind Study. *International Journal of Yoga*, 6, 39-46. <https://doi.org/10.4103/0973-6131.105945>
- Roy S, Kundu R, Medda S, Gupta A and Kaur BN, Evaluation of Proximal Femoral Geometry in Plain Anterior-Posterior Radiograph in Eastern-Indian Population, *J Clin Diagn Res*. 2014, 8(9): AC01–AC03.
- Tumusiime G, Kirum GG and Kukiriza, Morphometry of the Proximal End of Dry Adult Human Femora from the East African Population: A Cross- Section Study, *Austin Journal of Anatomy*, 2021, 54:203-215
- Kulkarni M, Naik A M, Shetty CB, Paruthikunnan SM, Rao SK: CT based measurement of anatomical dimensions of femur and its relevance in nail designs for proximal femoral fractures. *J Orthop*. 2020, 20:63- 69. 10.1016/j.jor.2019.12.002
- Chandran M, Kumar V: Reconstruction of femur length from its fragments in South Indian males . *J Forensic Leg Med*. 2012, 19:132-136. 10.1016/j.jflm.2011.12.010
- Robinson Jde D, Leighton RK, Trask K, Bogdan Y, Tornetta P 3rd. Periprosthetic Atypical Femoral Fractures in Patients on Long-term Bisphosphonates: A Multicenter Retrospective Review. *J Orthop Trauma*. 2016 Apr;30(4):170-6. doi: 10.1097/BOT.0000000000000508. PMID: 27003029.
- Isaac B, Vettivel S, Prasad R, Jeyaseelan L, Chandi G. Prediction of the femoral neck-shaft angle from the length of the femoral neck. *Clin Anat* 1997;10:318-23.
- Toogood PA, Skalak A, Cooperman DR. Proximal femoral anatomy in the normal human population. *Clin Orthop Relat Res*. 2009 Apr;467(4):876-85. doi: 10.1007/s11999-008-0473-3. Epub 2008 Aug 29. PMID: 18758876; PMCID: PMC2650061.