



Ameliorative potentials of methanol leaf extract of *Newbouldia laevis* on monosodium glutamate induced toxicity in female albino rats

Itez Paul¹, Aloh, Godwin S.², Osuocha, Kelechi U.^{3*}, Iwueke, Adaku V.⁴ and Chukwu, Ezinne C.⁵

¹Department of Biochemistry Michael Okpara University of Agriculture Umudike, Abia State. E-mail: paulo4millions@gmail.com

²Department of Biochemistry Michael Okpara University of Agriculture Umudike, Abia State. E-mail: godwinsundayaloh@gmail.com

³Biochemistry Unit Department of Science Laboratory Technology, Federal University of Lafia Nasarawa State. E-mail: osuochak@gmail.com

⁴Department of Biochemistry PAMO University of Medical Sciences, Rivers State. E-mail: drvivien.89@gmail.com

⁵Department of Biochemistry Federal University of Lafia Nasarawa State. E-mail: chukwuezinne@gmail.com

Article Info

Volume 2, Issue 3, July 2020

Received : 19 October 2019

Accepted : 25 March 2020

Published : 09 July 2020

doi: [10.33472/AFJBS.2.3.2020.37-50](https://doi.org/10.33472/AFJBS.2.3.2020.37-50)

Abstract

Newbouldia laevis is a valuable tropical plant belonging to the family of *Bigoniaceae*. The plant is believed by most herbal practitioners to be the tree of fertility and of immense medicinal benefits to humans. This study examined ameliorative potencies of *Newbouldia laevis* on monosodium glutamate induced toxicity in female albino rats for 14 days. Group A received 800 mg/kg body weight of Monosodium Glutamate (MSG), while Group B received 8,000 mg of MSG + 400 mg of extract. Group C received 8,000 mg of MSG and 600 mg of *N. laevis*. Group D received feed and water. Group E received 200 mg of extract and Group F received 8,000 mg of MSG. Results showed no significant difference ($p > 0.05$) in Aspartate Aminotransferase (AST), Alkaline Phosphatase (ALP) and Total Protein (TP) of rats exposed to MSG + extracts and MSG-alone. Significant ($p < 0.05$) elevation in Alanine Transferase (ALT) and serum albumin were recorded for rats exposed to MSG + 400 mg and 200 mg of extract. There was no significant difference in cholesterol level in rats exposed to MSG alone compared to other groups. Significant elevation in urea level occurred in rats exposed to 8,000 mg MSG + 600 mg of the extract, reduction occurred in those exposed to 8,000 mg MSG + 400 mg of the extract. Those exposed to normal saline and 200 mg of extract leveled up with rats exposed to MSG. Study indicates protection of liver architecture and ameliorating effect of *N. laevis* on MSG intoxication.

Keywords: Monosodium glutamate, *Newbouldia laevis*, Ameliorative, Potentials

© 2020 African Journal of Biological Sciences. This is an open access article under the CC BY license (<https://creativecommons.org/licenses/by/4.0/>), which permits unrestricted use, distribution, and reproduction in any medium, provided you give appropriate credit to the original author(s) and the source, provide a link to the Creative Commons license, and indicate if changes were made.

1. Introduction

Monosodium Glutamate (MSG) is one of the world's most extensively used food additives. It is the sodium of the non-essential amino acid glutamate. Glutamate is one of the most important abundant amino acids found in nature and exists both as free glutamate and bound with other amino acids into protein. Glutamate is the major excitatory neurotransmitter in the human and mammalian brain (Blaylock, 1999). As a consequence glutamate neurotransmitters is essential for cognition, memory movement, and sensation especially taste, sight and hearing (South, 1994). Though glutamate is an important neurotransmitter, excess glutamate is pumped back into the glial cells surrounding the neuron. This causes the nerve cells to be exposed to Fire constantly until they die (George, 2004). As flavor enhancer, MSG produces a flavor that cannot be provided by other foods additives. The name "monosodium glutamate" refers to a 99% pure combination of glutamic acid

* Corresponding author: Osuocha, Kelechi U., Biochemistry Unit Department of Science Laboratory Technology, Federal University of Lafia Nasarawa State. E-mail: osuochak@gmail.com

and sodium (George, 2004). Studies providing the evidence of MSG toxic effects have raised the increasing interest in MSG intake as flavor enhancer. *Newbouldia laevis* is also called boundary tree, which is usually grown as an ornamental tree and propagated by cuttings. It is a well-known plant on the Africa continent and is highly valuable due to its numerous immense benefits to humans. It is popularly known as the tree of fertility or tree of life (Agbafor et al., 2015; and Dandjesso et al., 2012;). It has different symbols and meanings to different countries, for example, some villages in Ivory Coast and Gabon plant the tree near the tombs to act as a protective talisman. The Ibibio and Efik people of Nigeria regard the tree as symbol of their deities thus they tend to place it in sacred places (Bafor and Sanni, 2009). It is generally believed that medicinal plants and their products are safer than their synthetic medicines depending on dosage (Boullata and Nace, 2000). This study is aimed at evaluating the ameliorative effect of *N. laevis* on MSG induced toxicity in female albino rats.

2. Experimental design

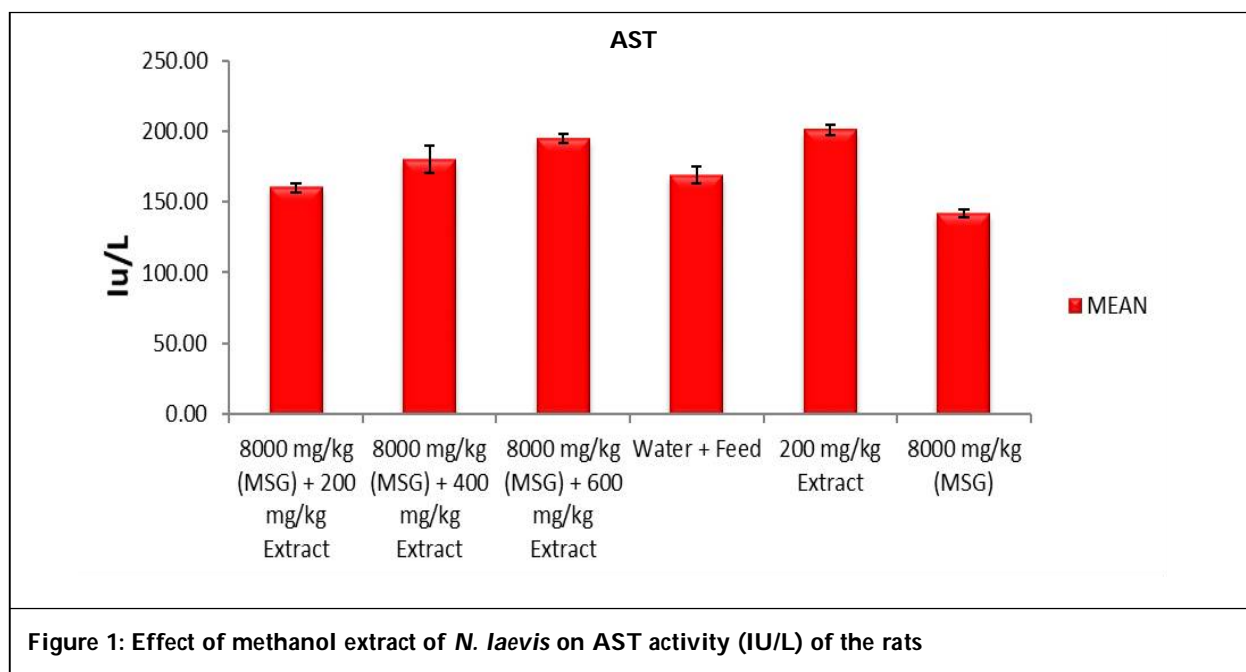
Thirty (30) female albino rats weighing 110-160 g were used for the analysis. The animals were randomly divided into six groups of animals. Group A rats were exposed to 8,000 mg/kg body weight of MSG and 200 mg/kg body weight of methanol leaf-extract for 14 days. Group B rats were concomitantly exposed to 8,000 mg/kg body weight of MSG and 400 mg/kg body weight of the methanol leaf-extract of *N. laevis* for 14 days. **Group C** rats were concomitantly exposed to 8,000 mg/kg body weight of MSG and 600 mg/kg body weight of methanol leaf extract of *N. laevis* for 14 days. Group D rats were exposed to neither MSG nor the sample extract (normal control group). Group E rats were concomitantly exposed to 200 mg/kg body weight of the sample (extract control) for 14 days. Group F was exposed to 8,000 mg/kg MSG for 14 days. The animals were kept in wire mesh cages and in standard laboratory conditions, with alternating light and dark cycles of 12 h each and at ambient temperatures, following seven days of acclimatization before commencement of experiment.

3. Determination of activities of liver enzymes

Aspartate Aminotransferase (AST), Alanine Transferase (ALT) activity were determined by the method of Reitman and Frankel (1957) while Alkaline Phosphatase (ALP) activity was assayed using the method of (King and Miller, 1957) while assay of blood urea nitrogen (BUN), serum creatinine were done by the method of Bauer et al., (1982), Assay of cholesterol and total protein was done using King and Wootton, method (1959).

4. Results

Figure 1 shows that the groups A and B with mean values 1.60 ± 3.45 and 1.80 ± 9.34 (IU/L) are significantly ($p < 0.05$) lower when compared with the group exposed to extract alone, 201.00 ± 3.40 (IU/L) and significantly ($p < 0.05$) higher when compared with the MSG-intoxicated group with mean value 142.30 ± 2.67 (IU/L).



A non-significant ($p > 0.05$) increase was also seen when compared with the normal control. Also, group C with mean value 194.65 ± 3.01 (IU/L) was significantly ($p < 0.05$) higher than the normal control and MSG-intoxicated groups while it shows a non-significant ($p > 0.05$) difference, compared with the positive control group.

Figure 2 shows that, the groups A and B with values 92.16 ± 1.00 (IU/L) and 99.89 ± 2.62 (IU/L), respectively are significantly ($p < 0.05$) lower than the MSG group (116.26 ± 4.18 IU/L) and non-significantly ($p > 0.05$) higher than the normal and MSG-intoxicated groups. Group A (99.89 ± 2.62 IU/L) showed a significant ($p < 0.05$) increase, compared to extract control group and a significant ($p < 0.05$) decrease, compared with the MSG-intoxicated group.

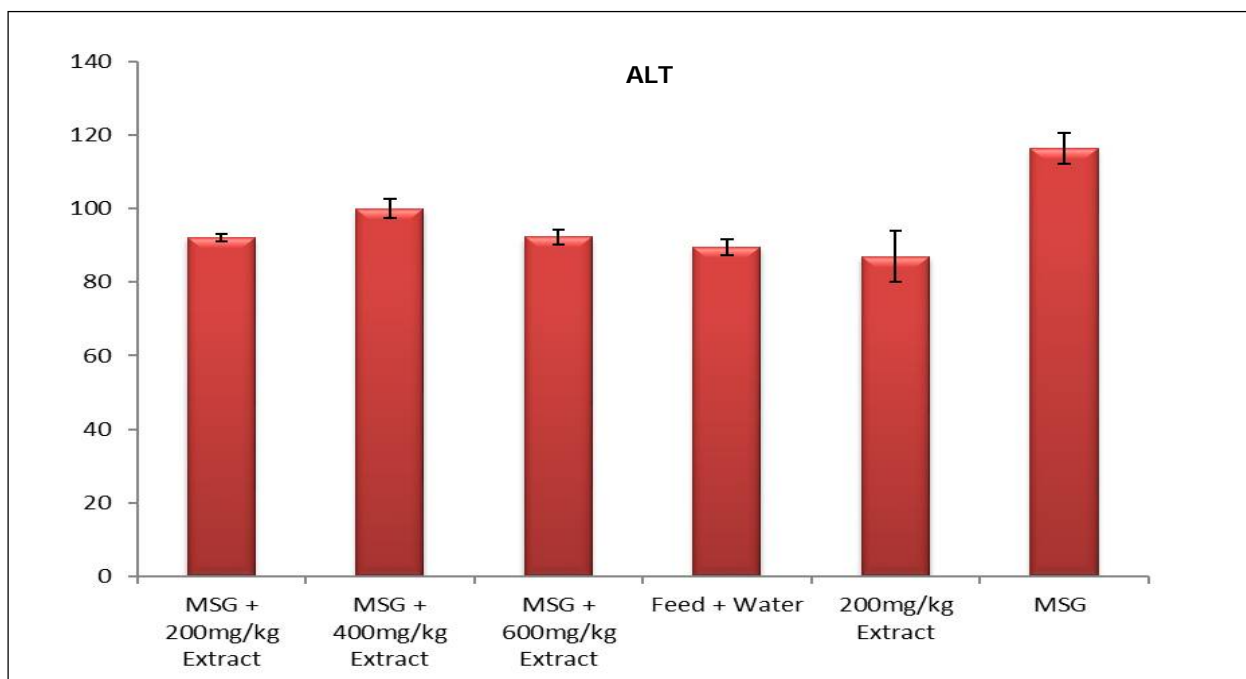


Figure 2: Effect of methanol extract of *N. laevis* on ALT activity (IU/L) of the rats

Figure 3 shows that, the groups A, B and C with mean values 18.15 ± 0.72 (IU/L), 17.71 ± 0.87 (IU/L) and 17.39 ± 0.57 (IU/L), respectively are significantly ($p < 0.05$) lower than the normal and extract control groups with

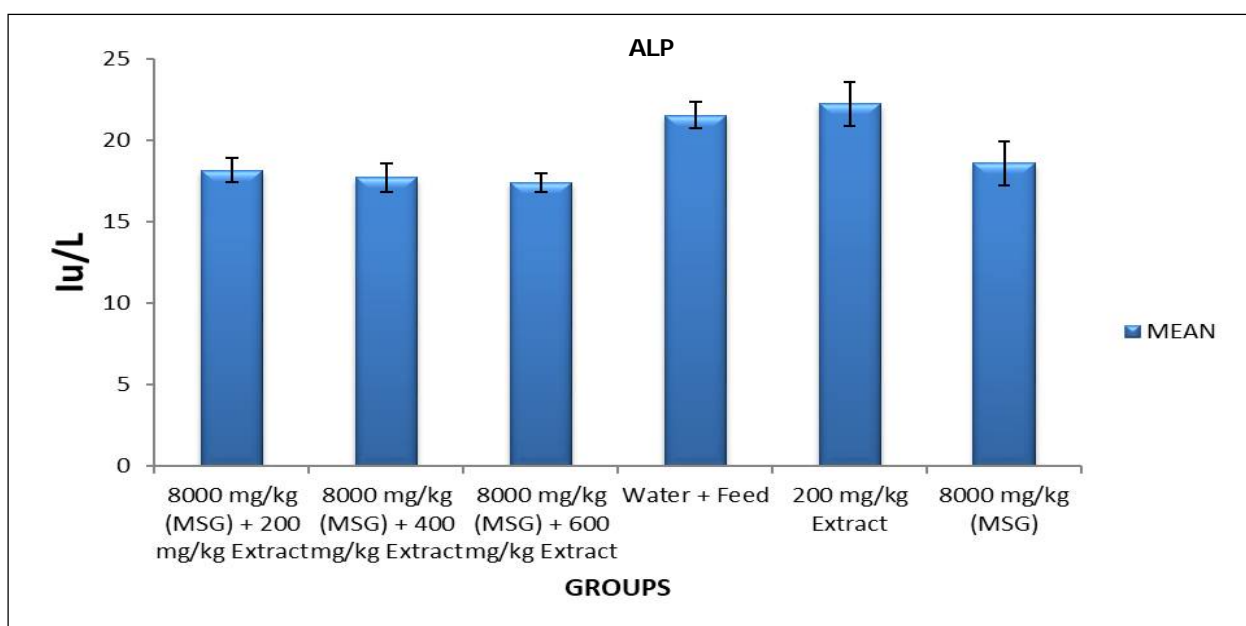


Figure 3: Effect of methanol extract of *N. laevis* on ALP activity (IU/L) of the rats

values 21.53 ± 0.82 (IU/L) and 22.22 ± 1.36 (IU/L), respectively while they are non-significantly ($p > 0.05$) lower than the MSG-intoxicated control group having a mean value of 18.57 ± 1.34 (IU/L).

Figure 3 shows that, the groups B and C with values 7.87 ± 0.38 (mg/dl) and 7.79 ± 0.63 (mg/dl), respectively are non-significantly ($p > 0.05$) higher than the normal, extract and MSG-intoxicated groups with values 7.52 ± 0.72 (mg/dl), 6.84 ± 0.44 (mg/dl) and 7.31 ± 0.55 (mg/dl), respectively while group A (6.18 ± 0.36 mg/dl) is non-significantly ($p > 0.05$) lower when compared with groups D, E and F.

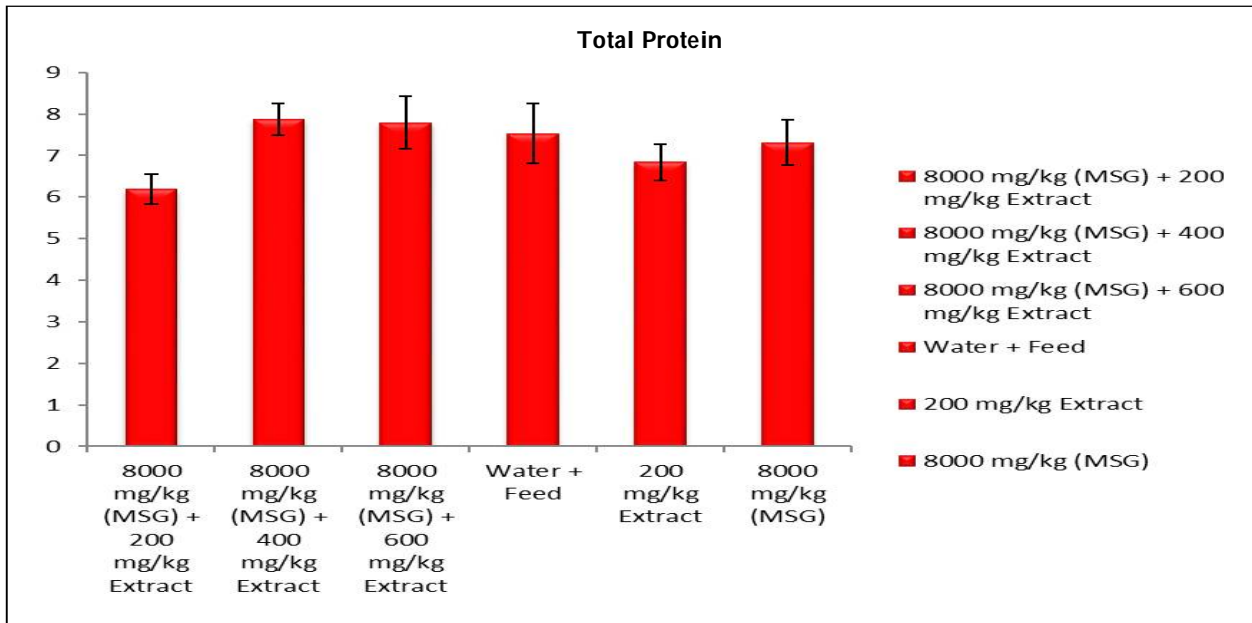


Figure 4: Effect of methanol extract of *N. laevis* on total protein concentration (mg/dl) of female albino rat

From the Figure 5, the groups A and C with mean values of 4.02 ± 0.31 (mg/dl) and 3.38 ± 0.32 (mg/dl), respectively are significantly ($p < 0.05$) lower when compared with the normal and group E exposed to extract alone, and non-significantly ($p > 0.05$) higher when compared with the MSG-intoxicated group (3.43 ± 0.14 mg/dl); while group B (5.69 ± 0.49 mg/dl) is significantly ($p < 0.05$) higher compared with MSG-intoxicated group and also, significantly ($p < 0.05$) lower when compared with the extract control groups.

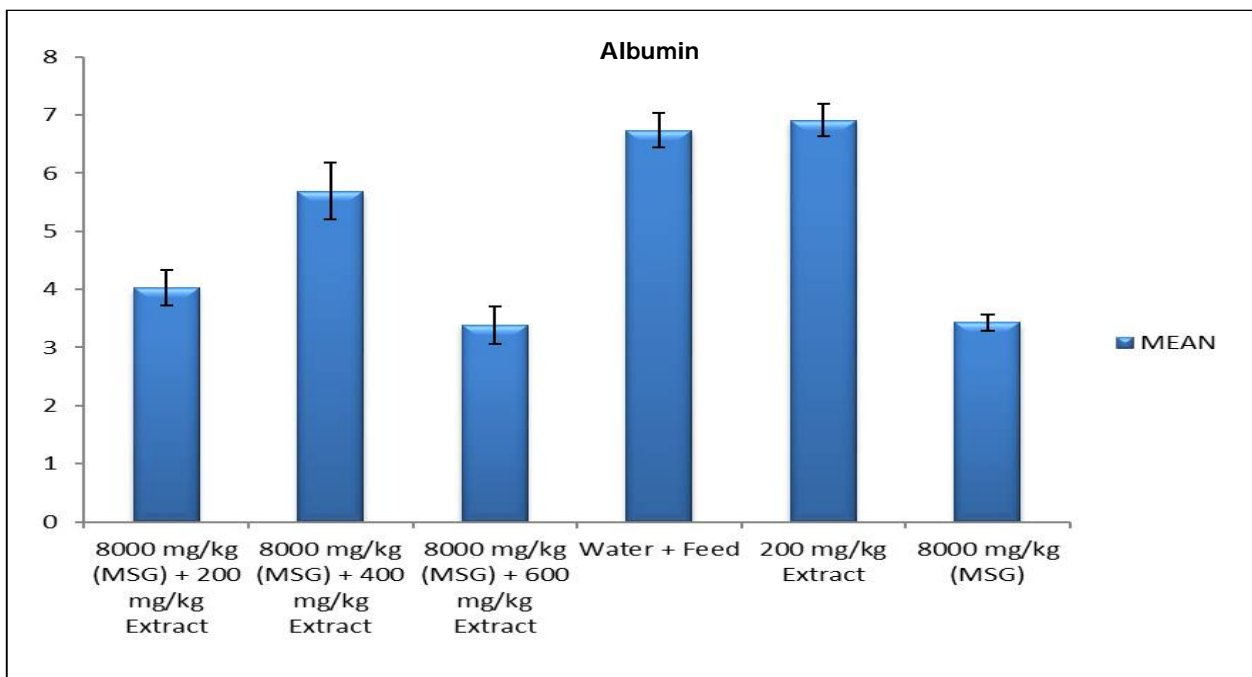


Figure 5: Effect of methanol extract of *N. laevis* on albumin concentration (mg/dl) of the rats

From the Figure 6, the group C of mean value, 4.38 ± 0.19 (mg/dl) was non-significantly ($p > 0.05$) higher than groups D, E controls and MSG-intoxicated group with mean values 4.16 ± 0.31 (mg/dl), 3.74 ± 0.23 (mg/dl) and 4.16 ± 0.25 (mg/dl), respectively while groups A and B with mean values as 3.86 ± 0.13 (mg/dl) and 3.70 ± 0.25 (mg/dl), respectively were non-significantly ($p > 0.05$) lower when compared with groups D, E and F.

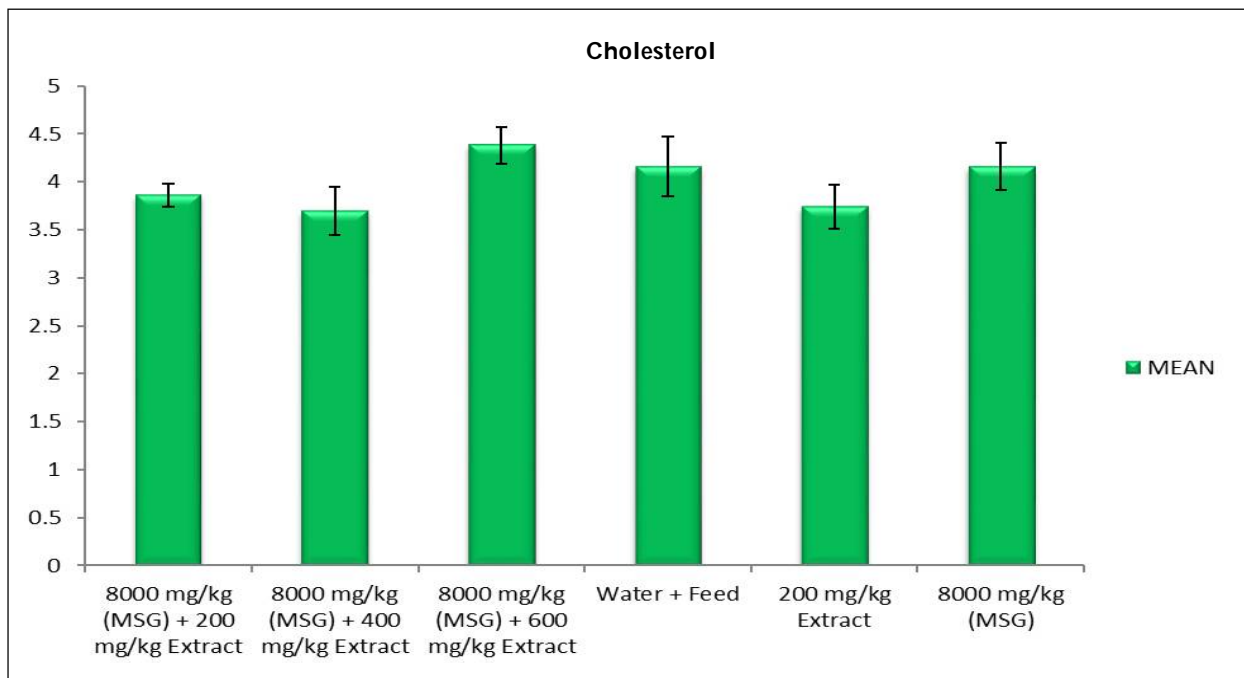


Figure 6: Effect of methanol extract of *N. laevis* on cholesterol (mg/dl) level of the rats

Figure 7 shows that, the group B with mean value 27.26 ± 2.73 (mg/dl) was significantly ($p < 0.05$) lower than the normal control group (33.84 ± 1.26 mg/dl) and non-significantly ($p > 0.05$) lower than groups E and F with values 32.53 ± 2.40 (mg/dl) and 31.85 ± 1.80 (mg/dl), respectively while groups A and C with values 28.76 ± 1.58 (mg/dl) and 37.27 ± 1.93 (mg/dl), respectively were non-significantly ($p > 0.05$) different when compared with groups D, E and F.

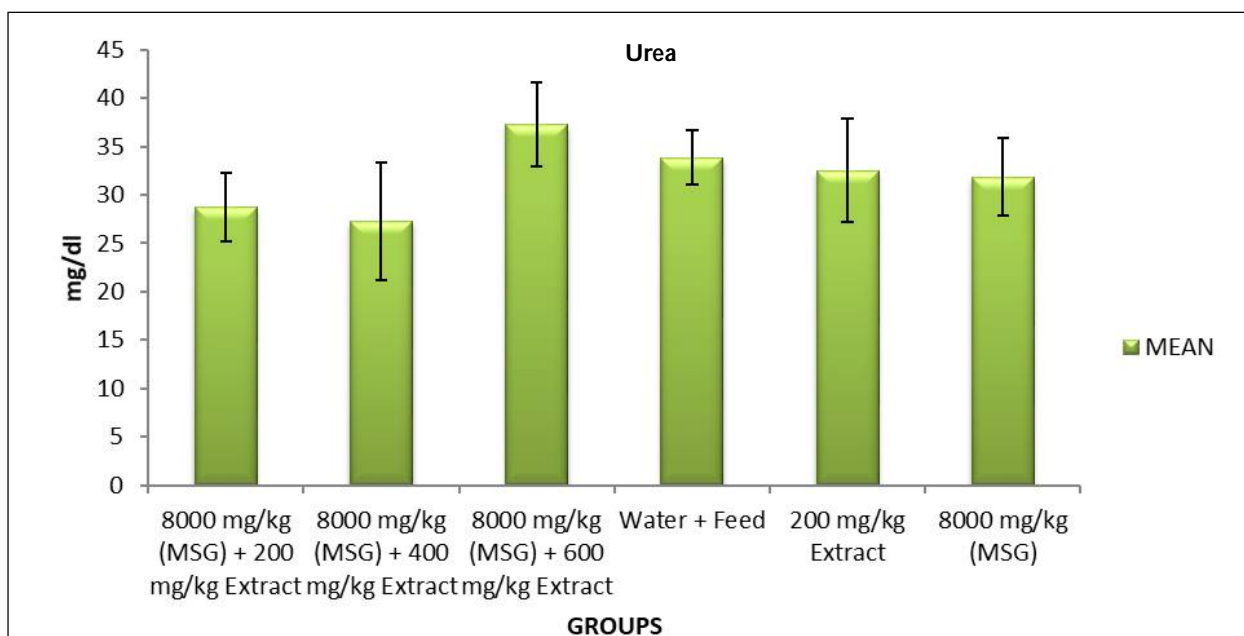


Figure 7: Effect of methanol extract of *N. laevis* on Urea concentration (mg/dl) of female albino rats

From the Figure 8, the groups A, B and C with mean values 1.00 ± 0.03 (mg/dl), 1.06 ± 0.05 (mg/dl) and 1.11 ± 0.06 (mg/dl), respectively showed a non-significant ($p > 0.05$) difference when compared with the normal, extract control and MSG-intoxicated group with values 0.99 ± 0.07 (mg/dl), 1.04 ± 0.02 (mg/dl) and 1.12 ± 0.04 (mg/dl), respectively.

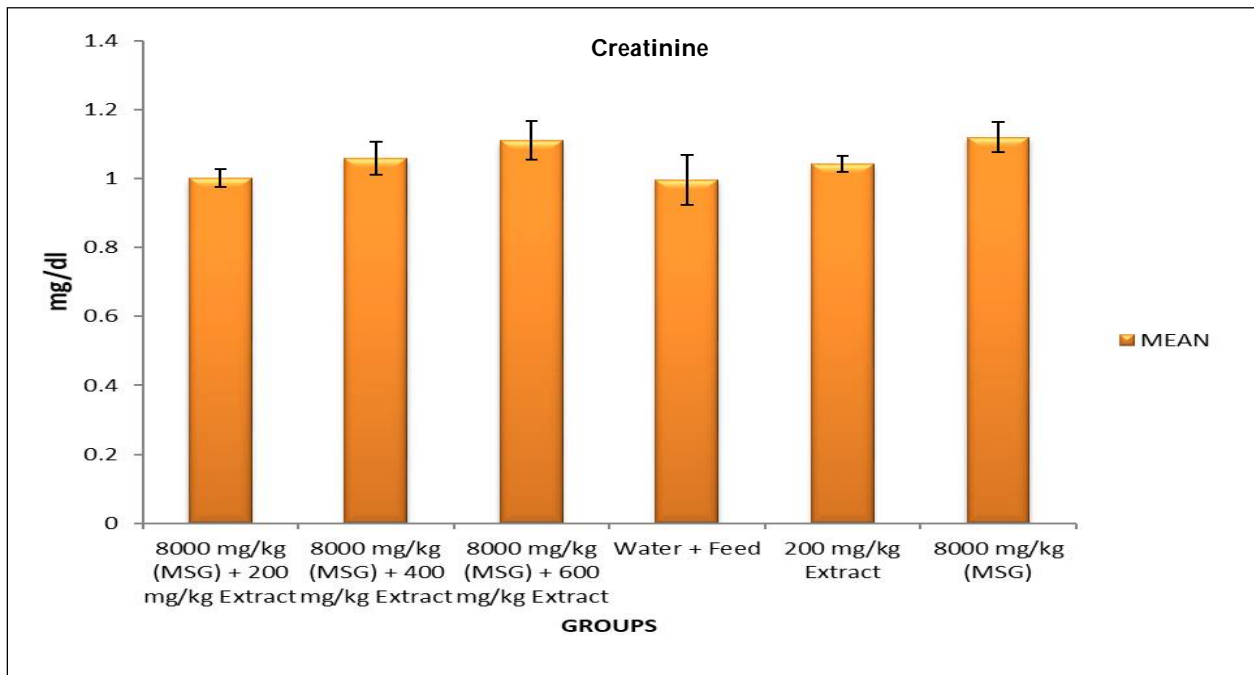


Figure 8: Effect of methanol extract of *N. laevis* on creatinine concentration (mg/dl) of the rats

The photomicrographs of the section of the liver of group A rats administered with 200 mg/kg of *N. laevis* + 8,000 mg/kg of MSG showed well preserved liver architecture. Presence of mild portal inflammation without necrosis, mild lobular hepatitis and normal central vein (Mg X400).

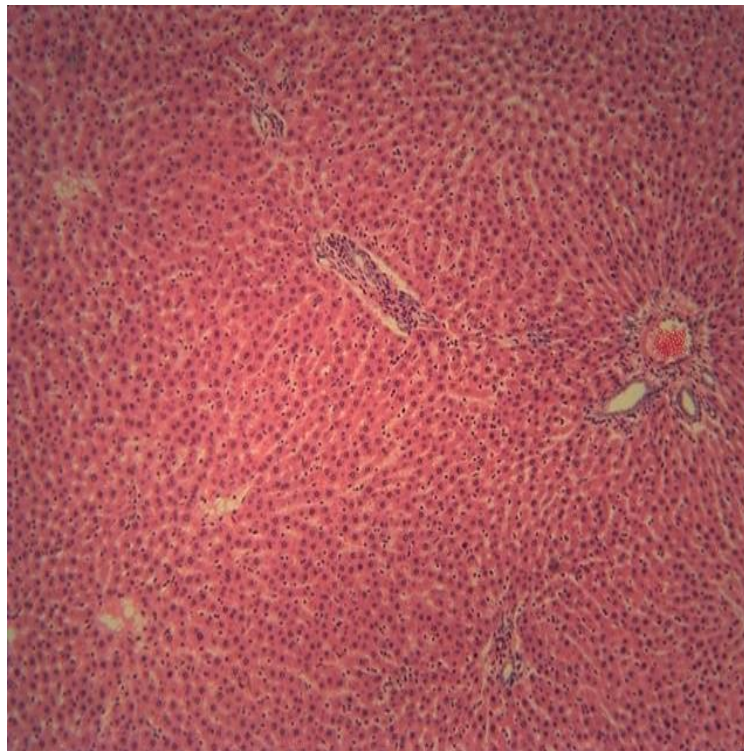


Plate 1: Effect of methanol extract of *N. laevis* on the liver of group A rats

Photomicrographs of the section of the liver of group B rats administered with 400 mg/kg leaf extract of *N. laevis* + 8,000 mg/kg MSG showed well preserved liver architecture, mild portal inflammation without interface hepatitis, mild lobular hepatitis without necrosis and steatosis and dilated central vein. (Mg X400)

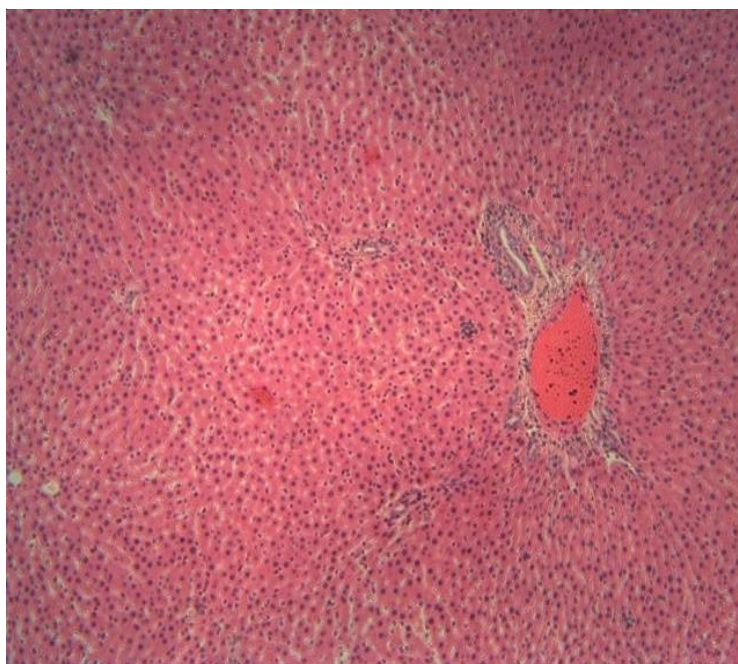


Plate 2: Effect of methanol extract of *N. laevis* on the liver of group B rats

Photomicrographs of the section of the liver of group C rats administered with 600 mg/kg leaf extract of *N. laevis* + 8,000 mg/kg MSG showed well preserved liver architecture, radially arranged hepatocytes, normal size nuclei, intervening sinusoids, and normal central vein (Mg X400).

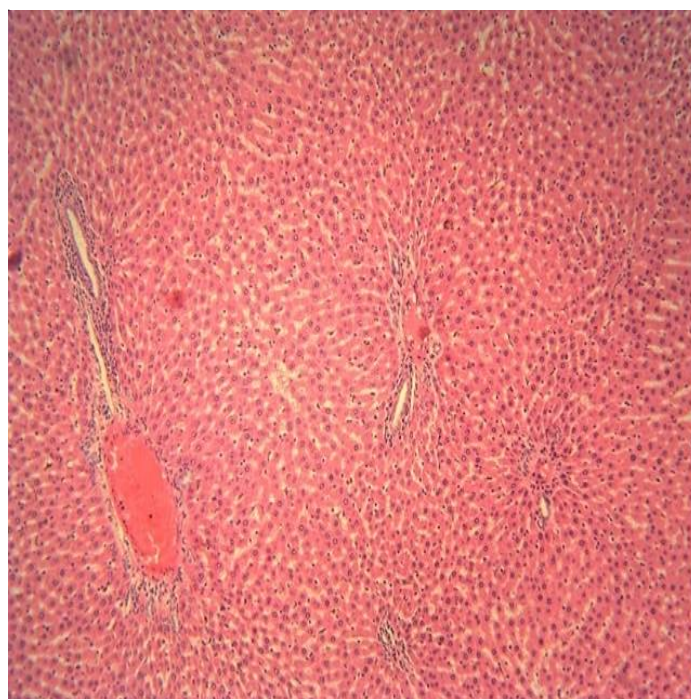

Plate 3: Effect of methanol extract of *N. laevis* on the liver of group C rats exposed to 600 mg/kg + 8,000 mg/kg of MSG

Photomicrographs of the liver section of normal control rats that received water and feed only (group 4) showed well preserved liver architecture with no histopathological lesion, and normal central vein. (Mg. X400).

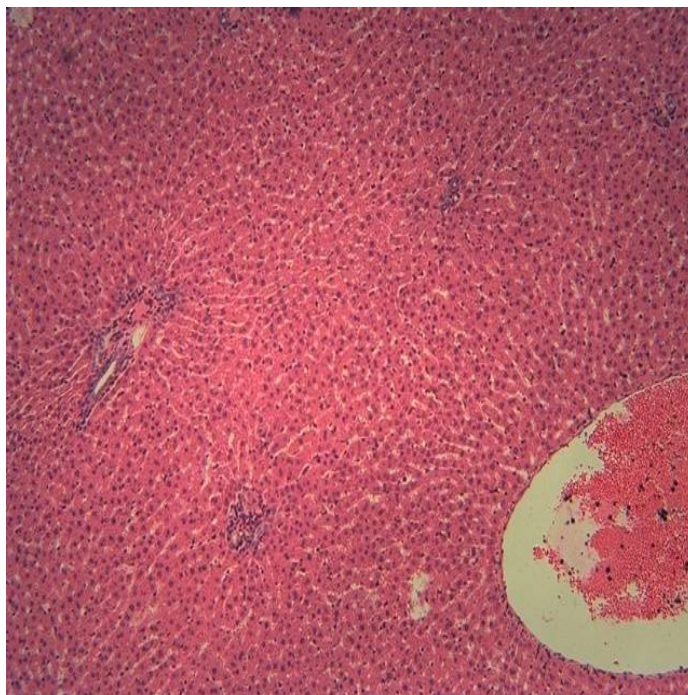


Plate 4: Effect of methanol extract of *N. laevis* on the liver of group D rats treated with water and feed only

Photomicrographs of the liver section of group E rats that received leaf extract of *N. laevis* 200 mg/kg only showed well preserved hepatocyte architecture, no portal inflammation, no lobular hepatitis or interstitial fibrosis, and mild steatosis (Mg X400).

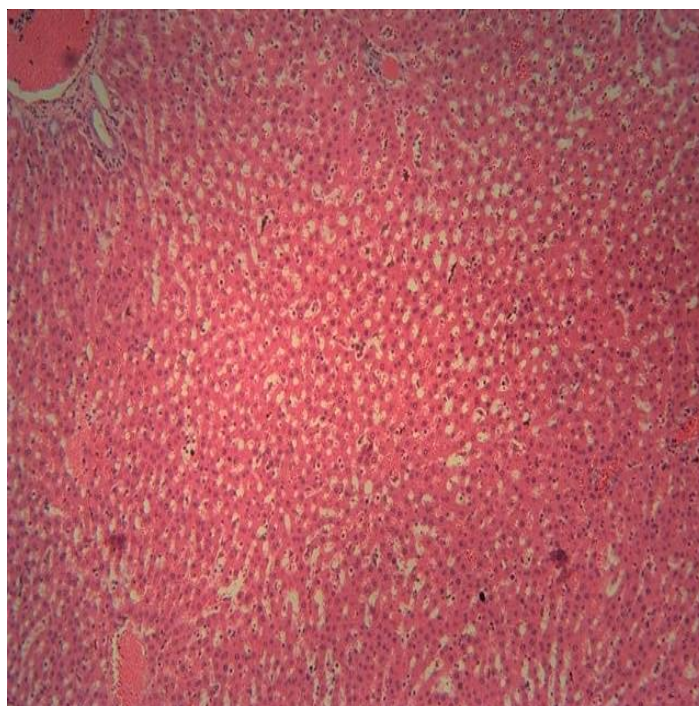


Plate 5: Effect of methanol extract of *N. laevis* on the liver of group E rats exposed to 200 mg/kgbw of extract of *N. laevis* only

Photomicrographs of the section of the liver of group F rats administered with 8,000 mg/kg MSG showed loss of normal hepatocytes architecture, nuclei of varying sizes and shapes, loss of sinusoidal spaces, presence of mild inflammatory cells and dilated central vein (Mg X400).

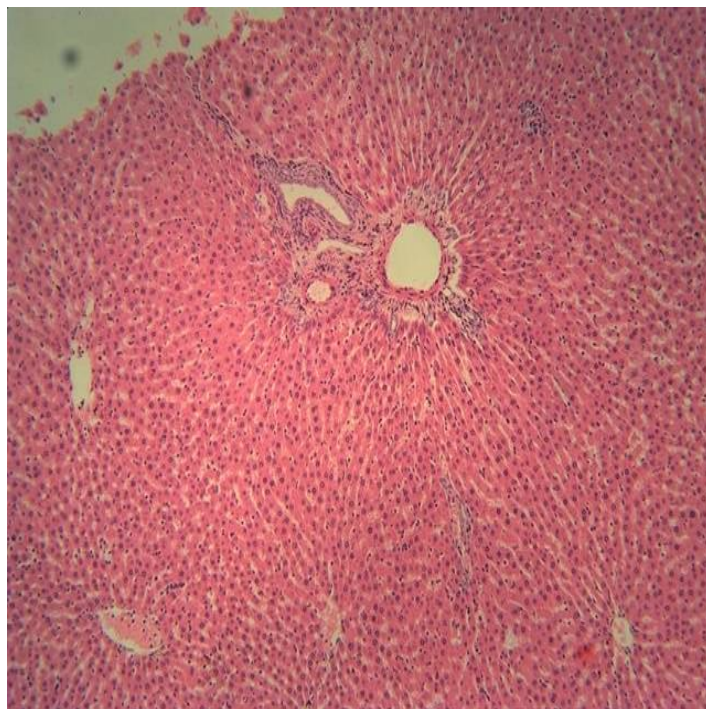


Plate 6: Effect of 8,000 mg/kg MSG on the liver of group F rats

Photomicrographs of the kidney section of group A rats administered with *N. laevis* 200 mg/kg + MSG 8,000 mg/kg showed evenly distributed glomeruli, open glomerular capillaries, normal endothelial epithelium with renal architecture, presence of thin distal and proximal tubules, presence of inflammatory cell (Mg. X400).

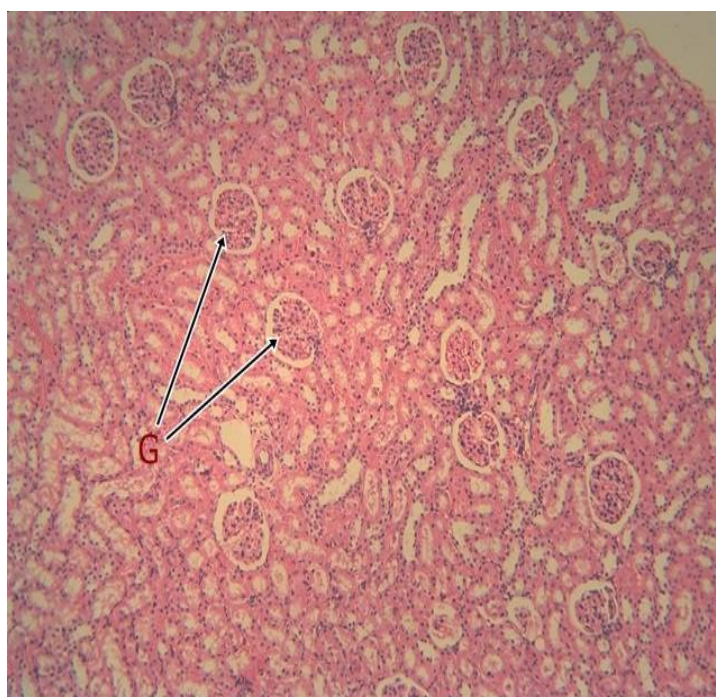

Plate 7: Effect of methanol extract of *N. laevis* on the kidney of group A rats administered methanol leaf extract of *N. laevis* 200 mg/kg + 8000 mg/kg MSG

Photomicrographs of the kidney section of group B rats administered with *N. laevis* 400 mg/kg + MSG 8,000 mg/kg showed evenly distributed glomeruli of normal size, density of up to 13 per HPF with normal mesangial cellularity and stroma, normal endothelial epithelium with renal architecture, open glomerular capillaries, presence of distal and proximal tubules (Mg. X400).

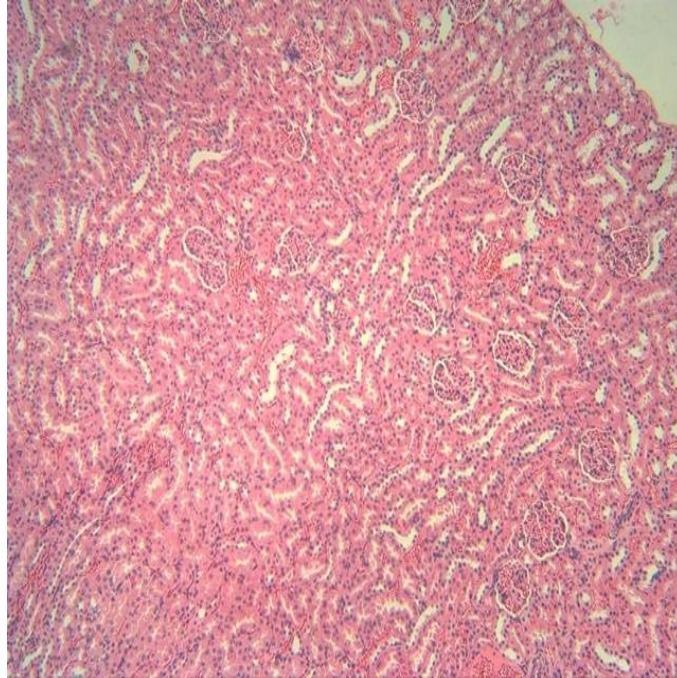


Plate 8: Effect of methanol extract of *N. laevis* on the kidney of group B rats administered methanol leaf extract of *N. laevis* 400 mg/kg + 8,000 mg/kg MSG

Photomicrographs of the kidney section of group C rats administered with *N. laevis* 600 mg/kg + MSG 8,000 mg/kg showed evenly distributed glomeruli of similar size, density of up to 9 per HPF, widening glomerular capillaries due to contraction of glomerulus, no presence of inflammatory cells (Mg. X400).

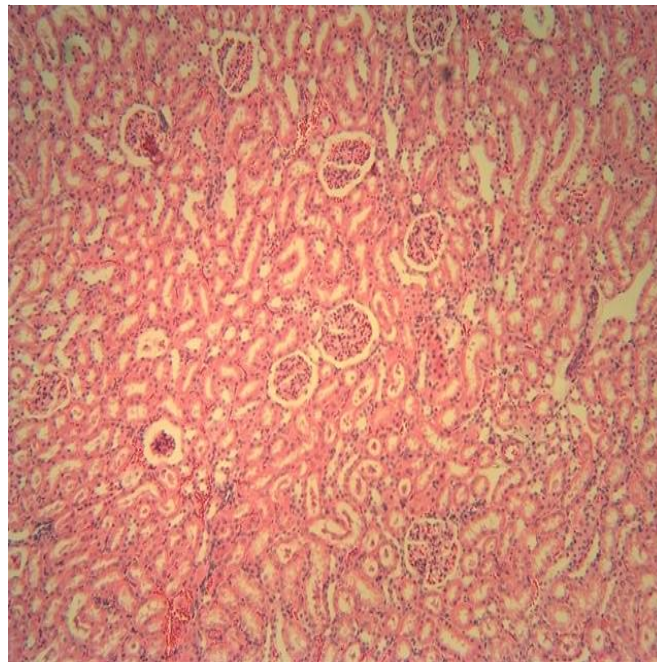


Plate 9: Effect of methanol extract of *N. laevis* on the kidney of group C rats administered leaf extract of *N. laevis* 600 mg/kg + 8,000 mg/kg MSG

Photomicrographs of the kidney section of group D or normal control rats administered with feed and water only showed normal kidney architecture, normal glomerular size of up to 17 per HPF with normal mesangial cellularity and stroma, presence of distal and proximal tubules and normal size nuclei (Mg. X400).

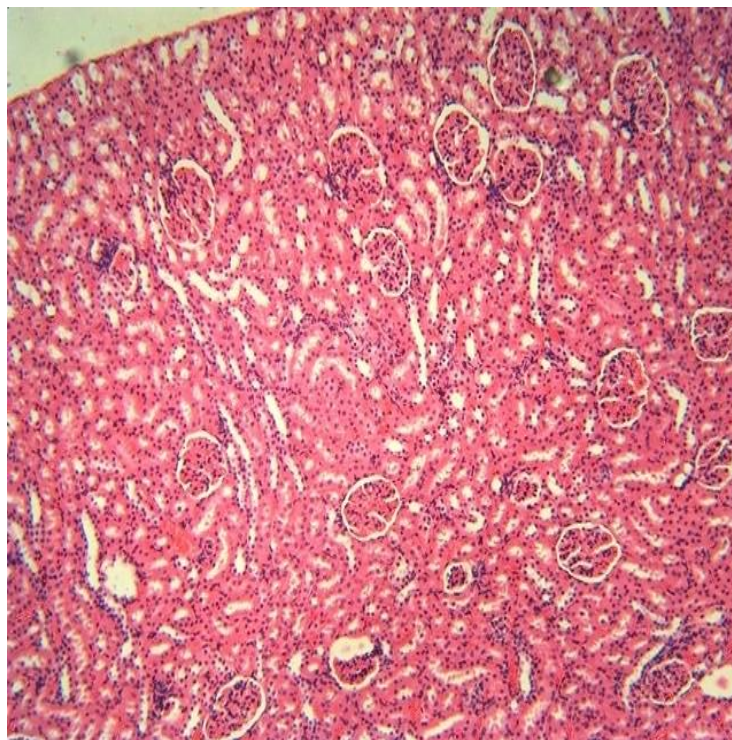


Plate 10: Effect of methanol extract of *N. laevis* on the kidney of group D (normal control) rats

Photomicrographs of the kidney section of group E rats administered with leaf extract of *N. laevis* 200 mg/kg alone showed intact glomeruli with kidney architecture, presence of distal and proximal tubules, normal size nuclei, and presence of mild inflammatory cells (Mg. X400).

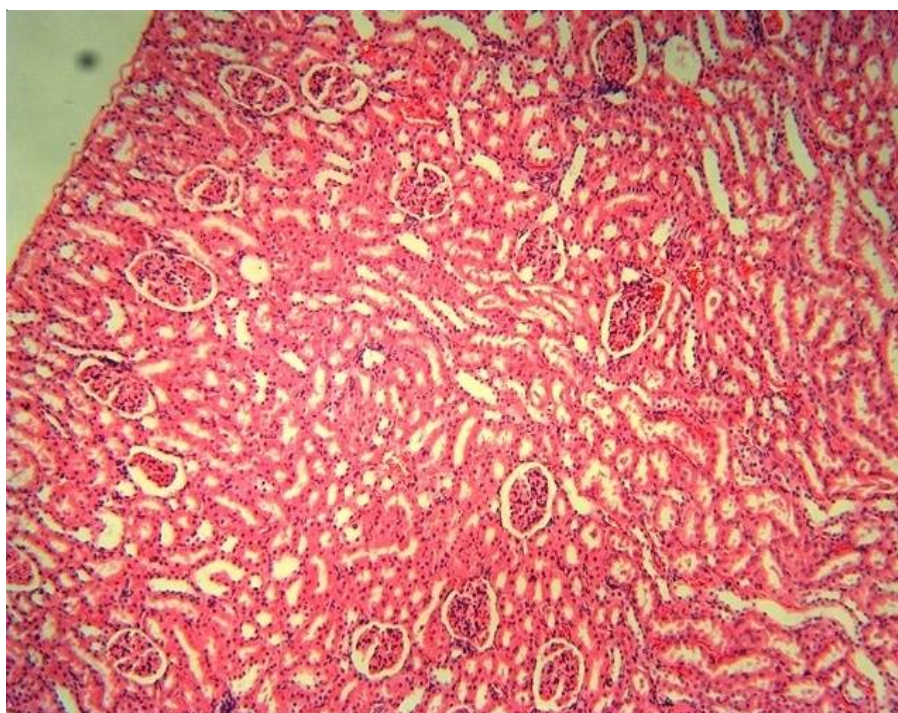


Plate 11: Effect of methanol extract of *N. laevis* on the kidney of group E rats administered 200 mg/kg of leaf extract of *N. laevis* only

Photomicrographs of the kidney section of group E rats administered with 8,000 mg/kg MSG alone showed widening of Bowman's space, contraction of distal and proximal tubules, and presence of mild inflammatory cells (Mg. X400).

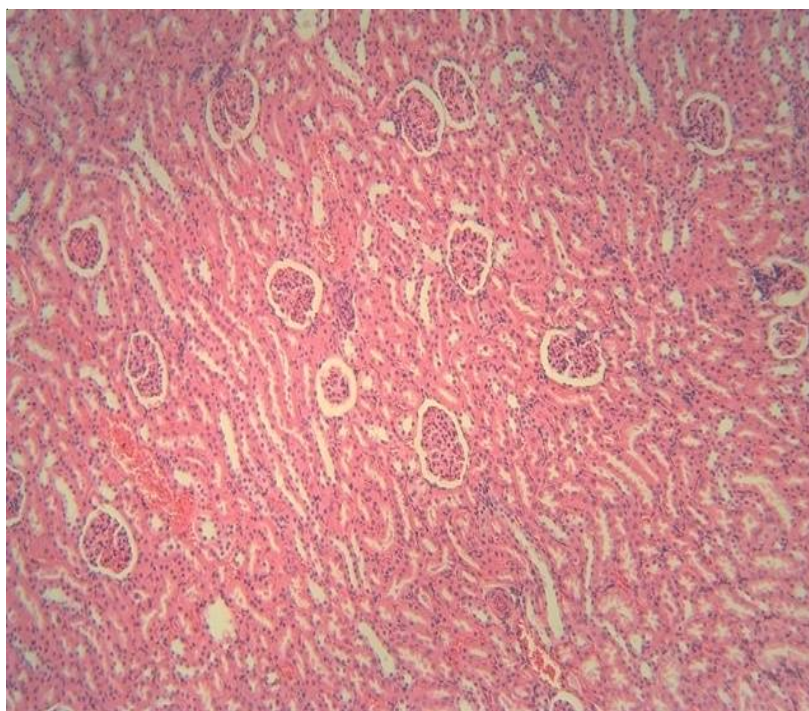


Plate 12: Effect of 8,000 mg/kg MSG on the kidney of group F rats

5. Discussion

Serum hepatic marker enzymes (AST, ALT and ALP) (Figures 1 to 3) were evaluated for hepatotoxicity. The liver is the most sensitive organ to pre-oxidative damage because it is rich in oxidizable substances. The more severe the liver damages, the higher the release of the liver enzymes (El-Khayat et al., 2009). However, significant elevations in serum level of AST, ALT and ALP with toxic substances may reflect damage of liver cells and cellular degeneration or destruction in this organ and the increase in the ALP activities in plasma might be due to the increased permeability of plasma membrane or cellular necrosis. When the liver cell membrane is damaged, varieties of enzymes normally located in the cytosol are released into the blood stream. Also, the elevation in ALP level in case of toxicity suggests an increase in lysosomal mobilization and cell necrosis (Kalendar et al., 2005). ALT is a cytoplasmic enzyme found in a very high concentration in the liver (Arbonnier, 2004). An increase in the serum level of this specific indicates hepatocellular damage. Although AST is less specific than ALT as a marker of liver enzymes is an indicator of tissue damage and altered membrane permeability (Saptal et al., 2010), while ALP is a marker of obstructive jaundice and intra-hepatic cholestasis (Daven et al., 2002).

Variation in cholesterol level (Figure 6) was insignificant within the groups, however, groups administered with MSG and extracts did not show significant ($p > 0.05$) elevated cholesterol level, which indicated that there is no possible interference with fat metabolism. The cholesterol pool in the intestine comes from dietary cholesterol and the majority from biliary excretion. Approximately 50% of the intestinal cholesterol pool is absorbed by intestine via extrahepatic circulation, with the remainder excreted in faeces (Grigore et al., 2007). The deviation from normal values of cholesterol, in the blood serum is considered as symptoms of liver diseases (Singh et al., 1988).

The measurement of blood urea is presently the most widely used screening test (creatinine) for the evaluation of kidney function. Renal disorder that lead to high blood urea levels include chronic nephritis, polycystic kidney, tubular necrosis and obstruction urinary tract (Renee et al., 2001). Serum urea in this report (Figure 7) did not show significant ($p > 0.05$) elevations in the groups administered with extract and MSG except in group C compared with control groups. Though the normal control group is not significantly ($p > 0.05$)

different compared with MSG exposed group. This showed that MSG-intoxicated rats have no indication of renal impairment or toxicity caused by MSG. However, some of the active ingredients in the extract in group C may have contributed to the elevation which is an indication of toxic injury to the kidneys; hence induce renal failure (Ijeh and Agbo, 2006). This result is in agreement with the findings of Mozes *et al.* (2004) which reported that MSG does not alter BUN level in MSG-exposed rats. Some pyrrolizidine alkaloids have been reported to contribute to renal tubular epithelium and glomerulosclerosis (Telcott, 2008). The blood serum samples of the rats treated with extract of 400 mg/kg contained low significant urea nitrogen compared with urea nitrogen mean values of the normal control.

MSG exposed or treated rats had no significant ($p > 0.05$) difference when compared with the controls. Absence of significant difference in MSG-treated rats with normal control group showed that MSG is not toxic to the kidneys at the above dose level for 14 days. Therefore, in the present study, serum creatinine was used to find out the effect of MSG on renal functional markers such as serum creatinine and serum urea nitrogen. A change in serum creatinine level is also an indicator of kidney function (Manal and Nawal, 2012).

Serum samples of the animals exposed to extract and MSG contained total protein whose mean values were not significantly ($p > 0.05$) different compared with normal control groups. Protein may be damaged directly by specific interaction of oxidants or free radicals with particularly susceptible amino acids due to toxicity or disease. This may lead to decrease in total protein (Narasimhanaidu and Ponnaian, 2006). The non significant ($p > 0.05$) decrease in the group of rats exposed to MSG compared with normal control group is an indication that MSG does not alter the synthesis of total protein. This finding is consistent with the reports on MSG non-toxicity in rats by Manal and Nawal (2012).

These results shows that albumin concentration (Fig 5) decreased significantly ($p < 0.05$) in the serum of MSG-intoxicated rats compared to normal control group. This implied that the synthetic function of liver was altered by MSG alone and group C and hence, decreased albumin level. Albumin concentration increased in the serum of MSG and extracts co-administered rats, except group C that recorded significant ($p < 0.05$) dose-dependent decrease in albumin (Figure 5). The observed reduction in albumin indicated liver damage arising from the uptake of the chemical compound (Naganna *et al.*, 1989). This may be an indication of diminished synthetic function of the liver which may consequently lead to enhanced retention of fluid in the tissues spaces (Naganna *et al.*, 1989). Results of histopathology study on the liver of only MSG-exposed rats (Plate 6) showed changes in histological patterns when viewed under the microscope at X400 magnification. Toxicity was evident by disruption of hepatic cords, varying sizes of nuclei, loss of sinusoidal spaces, portal inflammation and dilated central vein. The findings suggests that sub-chronic exposure to group C of MSG (8,000 mg/kg body weight) orally causes in the hepatocytes architecture or micro-anatomy inconsistent with similar reports written by Hellen *et al.* (2013) on MSG-induced toxicity in rats. Co-administration of methanol leaf extract of *N. laevis* helped to preserve the hepatocyte integrity as observed with less disruptions of liver micro-anatomy and inflammatory cells. The non-dose dependent ameliorating effect may be attributed to antioxidant properties of the methanol leaf extract of the *N. laevis*, which protects the liver from oxidative stress.

Similar results were also observed with MSG (8,000 mg/kg body weight) exposed rats. The loss or normal kidney architecture, varied nuclei sizes, varied glomerular opening with distal and proximal tubular contractions and presence of inflammatory cells. The methanol extract dosed groups showed normal renal micro-anatomy. This was as a result of ameliorating effect of the leaf extract of the *N. laevis*, which may be attributed to its renal protective effect. The little effects of the extract group alone on liver and kidney architectures with small amount of inflammatory cells in glomeruli, suggests MSG-toxicity dose-dependent effects of the extract.

6. Conclusion

The results from the animal studies confirmed toxicity on MSG-exposed rats, while the co-administration of methanol extract of *N. laevis* indicate its ameliorating efficacy on MSG-induced toxicities in rats via anti-oxidation mechanisms. This finding suggest that *N. laevis* extracts possess medicinal properties that may be effective in management of MSG toxicity.

References

- Arbonnier, M. (2004). *Trees, shrubs and lianas of west African dry zones*. CIRAD, MARGRAF publishers GMBH, MNHN. CTA Wageningen Netherlands, 18, 29-34.
- Bauer, J.H., Brooks, C.S and Burch, R.N (1982), Renal function studies in man with advanced renal insufficiency. *American Journal of Kidney Diseases*, 11, 30-35

- Agbafor, K. N., Ezeali, C. and Akubugwu, E. I. (2015). Anticonvulsant and analgesic properties of leaf and root extracts of *Newbouldia laevis*. *Asian Journal of Biochemistry*, 10, 299-305.
- Bafor, E. and Sanni, U. (2009). Uterine contractile effects of the aqueous and methanol leaf extract of *Newbouldia laevis* in vitro. *Indian Journal of Pharmacological Science*, 71, 124-126.
- Blaylock, R. L. (1999). Food additive excitotoxin and degenerative brain disorder. *Medical Science*, 4-6.
- Boullata, J. J. and Nace, A. M. (2000). Safety issues with herbal medicine. *Adverse Reaction*, 20: 257-269.
- Dandjesso, C., Klotee, J. R., Dougnon, T. V., Segbo, J. M., Gbaguidi, F., Fah, L., Fanou, B. A., Loko, F. and Drammane, K. (2012). Phytochemistry and homeostatic properties of some medicinal plants sold as antihemorrhagic in Cotonou markets. *Indian Journal of Science and Technology*, 5 (8), 3105-3109.
- Daven, T. J. and Scharschmidt, B. F. (2002). Biochemical liver tests. In: Feldman M, Friedman LS, Sleisenger MH (eds.) *Sleisenger & Fordtran's gastrointestinal and liver disease: pathophysiology, diagnosis, management*. 7th ed. Philadelphia: W.B. Saunders.
- El-Khayat, Z., Ahmed, R. E. Mohamoud, S. A., Wafaa, I. R. and Tahany, R. E. (2009). Potential effects of bee honey and propolis against the toxicity ochratoxin in rats. *Journal of Medical Science*, 311-318.
- George, J. G. (2004). The toxicity and safety of processed free glutamic acid. *Journal of Neuroscience*, 21, 8941-8952.
- Grigore, L., Norata, G. D. and Catapano, A. L. (2007). Inhibition of synthesis and absorption of cholesterol: A new option in managing hyper-cholesterolemia. *International Congress Series*, 1303, 121-128.
- Hellen, D. B., Maluly, M. A., Areas, P. B. and Felix, G. R. (2013). Evaluation of biochemical, histological and haematological parameters in non-diabetic and diabetic wistar rats fed with monosodium glutamate. *Food and Nutrition Science*, 4, 66-76.
- Ijeh, I. I and Agbo, C.A.C (2006). Body and organ weight changes following administration of aqueous extract of *Ficus exasperate* Vahl on white albino rats. *Journal of animal and veterinary Advances*, 5(4):277-279.
- Iwu, M. M. (2002). *Handbook of african medicinal plants*. CRC press, Inc., London, 1, 8-9.
- Kalender, S. A., Ogutcu, F., Acikgoz, P. and Kalender, Y. (2005). Diazinon-induced hepatotoxicity and protective effects of vitamin E on some biochemical indices and ultra-structural changes. *Toxicology*, 211, 197-206.
- King, E. J. and Miller, R. P. N. (1957). Alkaline phosphatase activity assay. *Clinical Pathology*, 7, 332.
- King, E. J. and Wootton, I. D. (1959). Total cholesterol determination in plasma/serum. In: *Microanalysis in Medical Biochemistry*. Churchill London, 42.
- Manal, S. and Nawal, A. (2012). Adverse effects of monosodium glutamate on liver and kidney functions in adult rats. *Food and Nutrition Science*, 3 (5), 2-7.
- Narasimhanaidu, K. and Ponnaian, S. M. (2006). Antihyperglycemic and antioxidant effect of rutin, polyphenolic flavonoid in streptozotocin-induced wistar rats. *Journal of Basic Clinical Pharmacology and Toxicology*, 98, 97-103.
- Naganna, B., Talwar, G. P., Srivastava, L. M. and Moudgil, K. D. (1989). *Textbook of Biochemistry and Human Biology* (2nd ed., pp. 59-61). New-Delhi: Prentice Hall of India private Ltd.
- Reitman, S. and Frankel, S. (1957). Colorimetric method for the determination of serum glutamate oxaloacetic and glutamic pyruvic transaminase. *American Journal of Clinical Pathology*, 28, 56-61.
- Renee, S. (2001). Urea and its blood levels. *Journal of Medical Association*, 3, 23-26.
- Saptal, S. K., Jain, J. and Punia, S. (2010). Studies on biochemical changes in subacute thiodicarb toxicity in rats. *Toxicology*, 17, 30-32.
- Singh, R. L., Khanna, S. K. and Singh, G. B. (1988). Acute and short term toxicity of a popular blend of yellow and orange II in albino rats. *Indian Journal of Experimental Biology*, 26 (2), 105-111.
- South, J. M. (1994). Glutamate neurotoxicity and diseases of nervous system. *Neuron*, 623-624.
- Telcott, P. (2008). *Pyrrrolizidine alkaloid poisoning: Current therapy in equine medicine* (5th ed., pp. 788-790) New-Delhi: W. B. Saunders.

Cite this article as: Itez Paul, Aloh, Godwin S., Osuocha, Kelechi U., Iwueke, Adaku V. and Chukwu, Ezinne C. (2020). Ameliorative potentials of methanol leaf extract of *Newbouldia laevis* on monosodium glutamate induced toxicity in female albino rats. *African Journal of Biological Sciences*, 2(3), 37-50.