



## The protective effects of *Telfairia occidentalis* on potassium bromate induced hepatotoxicity in adult Wistar rats

Busuyi Kolade Akinola<sup>1\*</sup>, Toluwase Solomon Olawuyi<sup>2</sup> and Adesua Emmanuel Ogunmokunwa<sup>3</sup>

<sup>1</sup>Department of Human Anatomy, Federal University of Technology Akure, P.M.B. 704, Akure, Nigeria.  
E-mail: [bkakinola@futa.edu.ng](mailto:bkakinola@futa.edu.ng)

<sup>2</sup>Department of Human Anatomy, Federal University of Technology Akure, P.M.B. 704, Akure, Nigeria.  
E-mail: [tsolawuyi@futa.edu.ng](mailto:tsolawuyi@futa.edu.ng)

<sup>3</sup>Department of Human Anatomy, Federal University of Technology Akure, P.M.B. 704, Akure, Nigeria.  
E-mail: [buskola4christ@gmail.com](mailto:buskola4christ@gmail.com)

### Article Info

Volume 2, Issue 3, July 2020

Received : 21 January 2020

Accepted : 15 April 2020

Published : 09 July 2020

doi: [10.33472/AFJBS.2.3.2020.51-61](https://doi.org/10.33472/AFJBS.2.3.2020.51-61)

### Abstract

Potassium bromate (KBrO<sub>3</sub>) used widely in foods have been classified as known human carcinogen with various complications associated with its use. *Telfairia occidentalis* is a medicinal plant with a number of pharmacological activities attributed to its extracts. This study was designed to investigate the protective effects of Aqueous Extract of *Telfairia occidentalis* (AETO) on potassium bromate-induced hepatotoxicity in adult Wistar rats. 20 Wistar rats obtained from the Animal House of the Biochemistry Department, FUTA, were acclimatized for one week. They were divided into four groups of five rats each. Group A received distilled water, Group B received 100 mg/kg body weight (b.w.) of KBrO<sub>3</sub>, Group C received 100 mg/kg b.w. of KBrO<sub>3</sub> and 200 mg/kg b.w. of AETO, and Group D received 100 mg/kg b.w. of KBrO<sub>3</sub> with 500 mg/kg b.w. of AETO concomitantly for 21 days. Results obtained revealed that exposure of rats to KBrO<sub>3</sub> caused loss of normal histoarchitecture, hepatocellular injury and degeneration as well as decreasing hematological parameters. However, administration of AETO with KBrO<sub>3</sub> ameliorated the induced-hepatic injury at the same time increasing the hematological parameters. Conclusively, AETO offer protective effects by restoring the structural integrity of the liver and increasing the level of blood parameters which was initially decreased by KBrO<sub>3</sub>.

**Keywords:** Potassium bromate, *Telfairia occidentalis*, Hepatotoxicity, Hematology

© 2020 African Journal of Biological Sciences. This is an open access article under the CC BY license (<https://creativecommons.org/licenses/by/4.0/>), which permits unrestricted use, distribution, and reproduction in any medium, provided you give appropriate credit to the original author(s) and the source, provide a link to the Creative Commons license, and indicate if changes were made.

### 1. Introduction

Leafy vegetables are important items of diet in every home. Apart from the variety which they add to the menu, they are important sources of nutrients especially in rural areas where they contribute in large amount to protein, mineral, vitamins, fiber and other nutrients which are usually in short supply in common daily diets (Mosha and Gaga, 1999).

Potassium bromate is a white crystal, granule or powder, which is colorless, odorless, and tasteless. It has no medicinal importance but is added to flour as a maturing agent (Chipman et al., 1998). Bromate was first discovered to cause tumors in rats in 1982, and subsequent studies validate its damage to the kidney, liver, thyroid and other organs (Dimkpa et al., 2013; and Halliwell et al., 1989).

\* Corresponding author: Busuyi Kolade Akinola, Department of Human Anatomy, Federal University of Technology, P.M.B. 704, Akure, Nigeria. E-mail: [bkakinola@futa.edu.ng](mailto:bkakinola@futa.edu.ng)

*Telfairia occidentalis* is a medicinal plant with a number of pharmacological activities ascribed to its extracts. Traditionally, it is used to increase blood volume in anemic patients and in the treatment of liver disease and high blood sugar problem (Eseyin et al., 2005 and Adaramoye et al., 2007). It has been reported that the extracts of *Telfairia occidentalis* gotten from the usage of different solvents offered protective and chemopreventive effects on oxidative stress-induced organs like brain, liver, and kidney (Hamza et al., 2013). It was also reported that the hepatoprotective characteristics of the polyphenol contents of *Telfairia occidentalis* leaves on acetaminophen-induced liver damage (Nwanna and Oboh, 2007). Therefore, the consumption of *Telfairia occidentalis* leaves should provide sufficient antioxidants that can prevent the effects of oxygen-reacting species and promote the general well-being of animals. It is to this end that this study was carried out to evaluate the protective effect of aqueous leaf extracts of *Telfairia occidentalis* against potassium bromate-induced hepatotoxicity and histopathological abnormalities.

## 2. Materials and methods

### 2.1. Apparatus and chemicals used

Potassium bromate, Formalin 10%, Finisher Feed Top Feed Ltd. Other material includes; microscope, microscope slides, measuring cylinder, sterilized containers, syringe 5 ml, oral cannula, Lithium-heparin bottles, cotton wool, dissecting kit/surgical apparatus.

### 2.2. Collection of plant samples

The fresh leaves of *Telfairia occidentalis* were purchased from Akure market in Ondo state, Nigeria. Authentication of the leaves was carried out in the Department of Crop Science and Production, Federal University of Technology Akure, Ondo State, Nigeria, and was air dried for four days before being ground into powdery form using an electronic grinding machine.

### 2.3. Preparation of aqueous extract

A 260 g of the powdered *Telfairia occidentalis* was measured and soaked in 1,300 ml of distilled water for 48 h with mixing at intervals afterwards filtered using a muslin cloth. The filtrate was thus concentrated using a Rotary evaporator followed by drying in vacuum oven at 50 °C. The dry thick slurry was transferred into a dry sample bottle and stored at -5 °C until use.

### 2.4. Experimental animals

Twenty Wistar rats weighing between 120-220 g were used for this experiment. The rats were obtained from Central Animal House of the Biochemistry Department, Federal University of Technology Akure, Ondo state, Nigeria. The rats were kept in ventilated cages at optimum temperature and 12 h light/dark cycle. The animals were fed with standard laboratory animal diet and water ad libitum. The experiment was carried out in accordance with current rules and guidelines that have been established for the care of the laboratory animals (NRC, 2011).

The rats were acclimatized for seven days before treatment commenced.

### 2.5. Experimental design and dose regimen

The 20 Wistar rats were randomly assigned into four (4) different groups containing five (5) rats each. The body weight and the average weight of each group were taken and recorded weekly.

- **Group A** received only normal feed and water
- **Group B** received 100 mg/kg of potassium bromate (KBrO<sub>3</sub>) only once daily for 21 days.
- **Group C** received 100 mg/kg of potassium bromate (KBrO<sub>3</sub>) and 200 mg/kg body weight of the Aqueous Extract of *Telfairia occidentalis* (AETO) daily for 21 days.
- **Group D** received 100 mg/kg of potassium bromate (KBrO<sub>3</sub>) and 500 mg/kg body weight of the AETO daily for 21 days.

### 2.6. Sacrifice of experimental animals and sample collection

The rats were weighed and sacrificed after 24 h of last dose treatment by cervical dislocation. The livers were harvested immediately and fixed in 10% formal saline, after which the tissue was processed for staining.

2 mL of blood was collected by cardiac puncture into properly labeled sterilized bottles containing Lithium-Heparin as anticoagulant for hematological analysis.

### 2.7. Histological examination

The livers were fixed immediately in 10% formal saline and embedded in paraffin wax. A fine section of the liver was dewaxed in xylene, hydrated in decreasing percentage of alcohol and stained with hematoxylin and eosin. The stained section was observed under a microscope and their photomicrograph was taken at varying magnifications with a digital camera (Image J).

### 2.8. Hematological examination

The Hematocrit (HCT), Red Blood Cell (RBC), White Blood Cell (WBC), Hemoglobin Concentration (HGB), Mean Corpuscular Hemoglobin Concentration (MCHC), Mean Corpuscular Volume (MCV), Lymphocyte (LYMPH), Platelet (PLT), were measured using Mindray (BC-5390) Auto Hematology Analyzer.

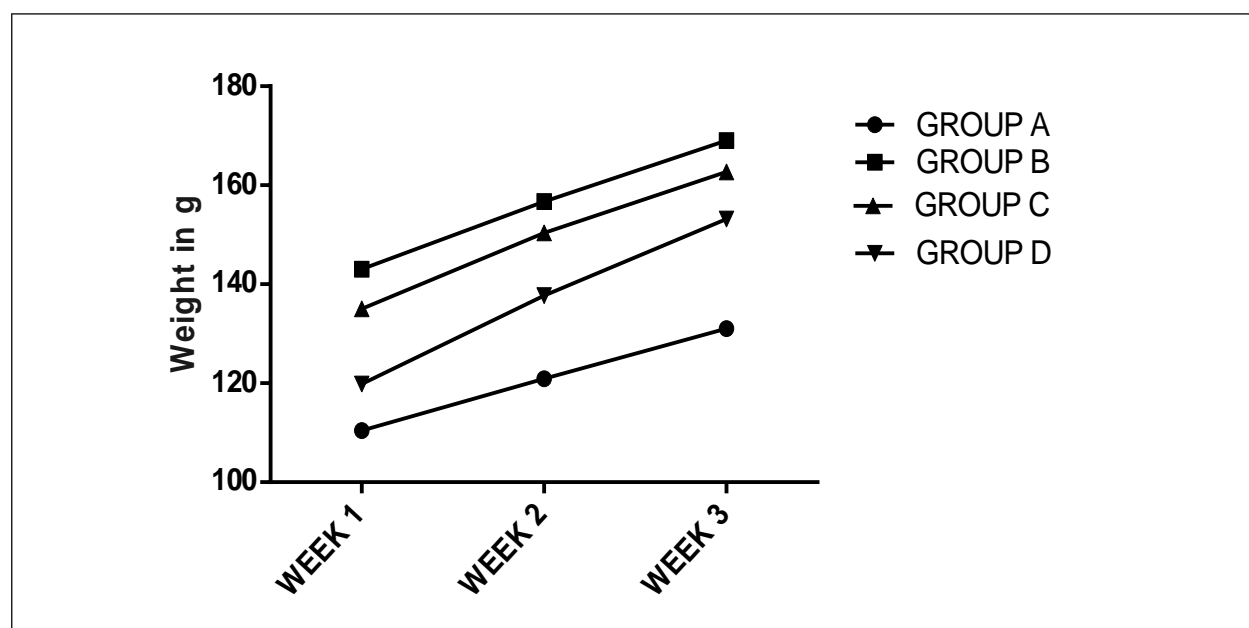
### 3. Statistical analysis

All data obtained were subjected to statistical analysis. Values were expressed as Mean  $\pm$  Standard Error of Mean (SEM) while One way ANOVA was used to test for differences between treatment groups using Graphpad Prism. The results were considered significant at  $p$ -values less than 0.05 ( $p < 0.05$ ). These were then presented with suitable charts. In addition, histological evaluation was presented with tissue micrograph H and E  $\times$  100.

### 4. Results

#### 4.1. Observatory report on body weights of rats

Figure 1 shows the weight gain observed across the groups. There was an increase in body weight among  $KBrO_3$ -induced rats (group B) when compared with the control group (A). Groups treated with 200 mg and 500 mg AETO (C and D) shows a significant increase in body weight when compared with the normal (control) group.



**Figure 1: Weight changes observed in rats across groups**

**Note:** A line graph showing the change in body weight of rats across the groups. Results are represented as Mean  $\pm$  Standard Error of Mean (SEM),  $n = 5$  rats in each group. Each value represented as Mean  $\pm$  SEM,  $n = 5$  readings. Value of  $p < 0.05$  was considered significant. The values with superscript  $\alpha =$  significantly different from group A,  $\beta =$  different from group B.

#### 4.2. Histological sections of the liver across groups

The results of the histology were shown in plates 1 and 2 below. The photomicrograph of the histological sections across groups revealed that the administration of AETO tends to ameliorate the cytoarchitectural and histomorphological distortions of the liver of groups C and D (treated groups) when compared to group B (induced with 100 mg/kg b.w. of  $KBrO_3$  but not treated). The observation of the control group (A) showed normal liver morphology. This is in complete contrast to group B which showed structural disorganization typical of liver damage.

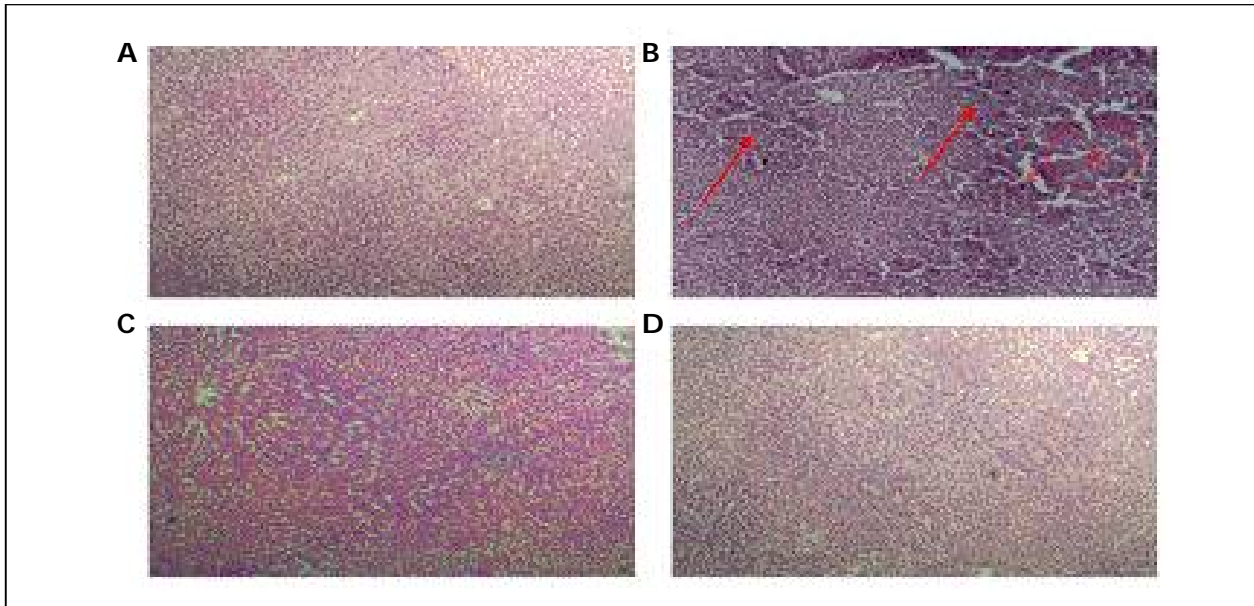


Plate 1: Photomicrograph of liver histology for group A (control group) with normal liver histologic features; group B (induced with 100 mg/kg b.w. of  $KBrO_3$ ) with complete loss of cyto and histoarchitecture showing dilated portal area (dp), portal area infiltrated by inflammatory cells, dilated sinusoids (c), hepatocyte necrosis (yellow arrow), karyolysis (black arrow) and pyknosis (green arrow); group C (induced with  $KBrO_3$  and treated with 200 mg/kg b.w. of AETO) showing signs of recovery in the hepatocytes and central vein; group D (induced with 100 mg/kg b.w. of  $KBrO_3$  and treated with 500 mg/kg b.w. of AETO) showing a nearly normal liver histoarchitecture. H & E; Magnification X40.

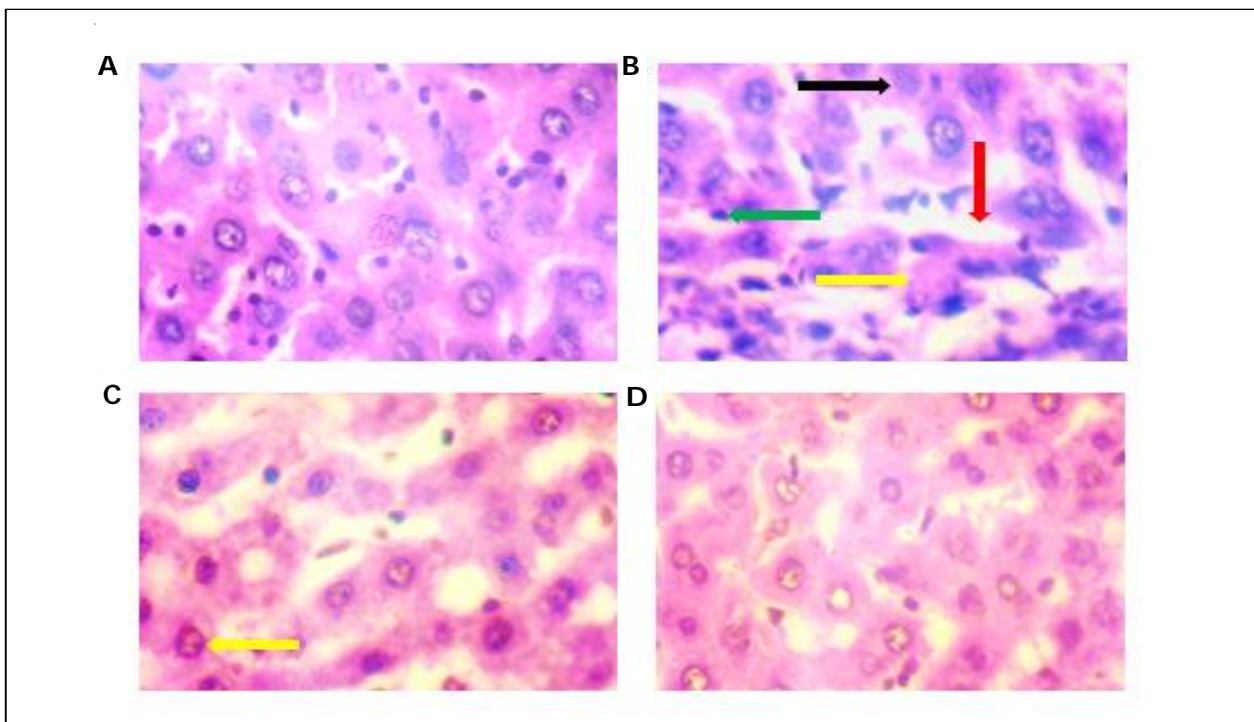
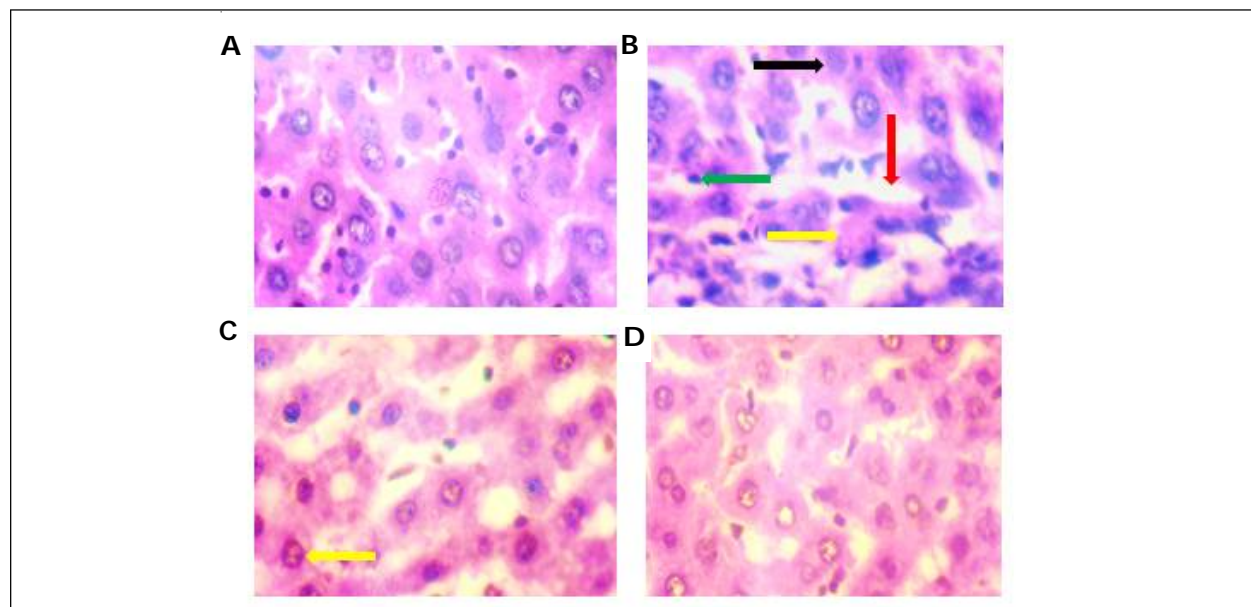


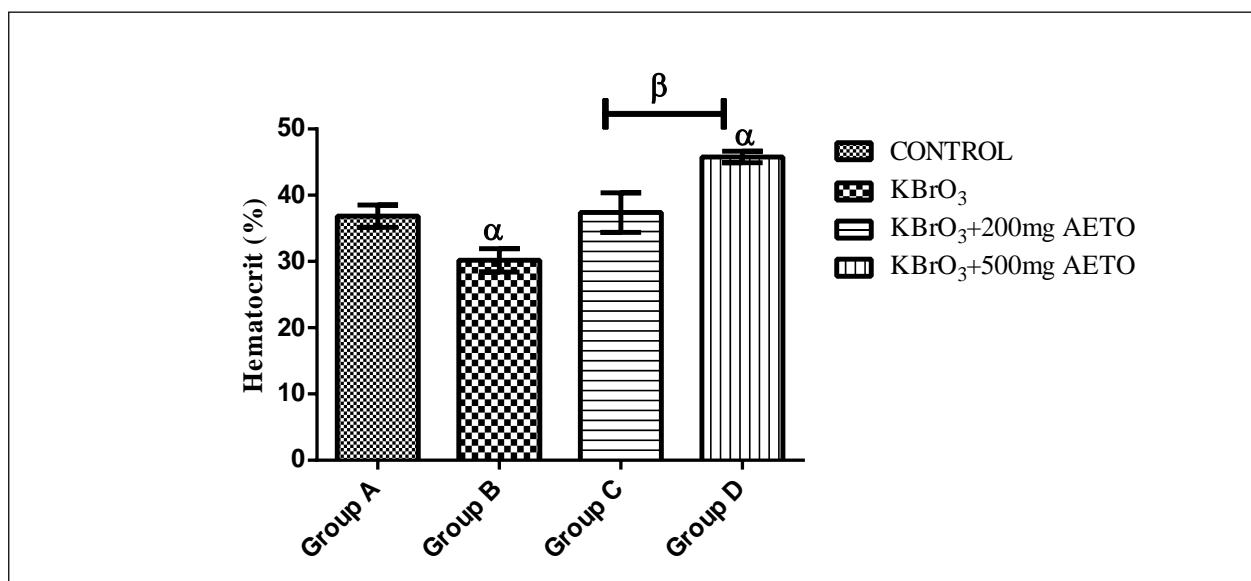
Plate 2: Photomicrograph of liver histology for group A (control group) with normal liver histologic features; group B (induced with 100 mg/kg b.w. of  $KBrO_3$ ) with loss of cyto and histoarchitecture showing dilated portal area (dp), portal area infiltrated by inflammatory cells, dilated sinusoids (red arrow), hepatocyte necrosis (yellow arrow), karyolysis (black arrow) and pyknosis (green arrow); group C (induced with  $KBrO_3$  and treated with 200 mg/kg b.w. of AETO) showing signs of recovery in the hepatocytes and central vein; group D (induced with 100 mg/kg b.w. of  $KBrO_3$  and treated with 500 mg/kg b.w. of AETO) showing a nearly normal liver histoarchitecture. H & E; Magnification X100.



**Plate 3: Photomicrograph of liver histology for group A (control group) with normal liver histologic features; group B (induced with 100 mg/kg b.w. of  $KBrO_3$ ) with loss of cyto and histoarchitecture showing dilated portal area (dp), dilated sinusoids (red arrow), hepatocyte necrosis (yellow arrow), karyolysis (black arrow) and pyknosis (green arrow); group C (induced with  $KBrO_3$  and treated with 200 mg/kg b.w. of AETO) showing signs of recovery in the hepatocytes and central vein; group D (induced with 100 mg/kg b.w. of  $KBrO_3$  and treated with 500 mg/kg b.w. of AETO) showing a nearly normal liver histoarchitecture. H & E; Magnification X400.**

#### 4.3. Effect of AETO on hematocrit concentration

Figure 2 illustrates the effects of AETO on haematocrit concentration in the serum of rats with potassium bromate-induced hepatotoxicity. There was a significant decrease ( $p < 0.05$ ) in the serum level of HCT in rats group induced with  $KBrO_3$  (group B) when compared with the normal (control) group. The serum level of group D shows a significant increase in HCT level when compared with the potassium bromate-induced group (group B). There was also a dose-dependent difference between the treated groups (C and D) when compared to each other.



**Figure 2: Effects of AETO on serum HCT activity**

**Note:** Each value represented Mean  $\pm$  SEM,  $n = 5$  readings. Value of  $p < 0.05$  was considered significant. The values with superscript  $\alpha$  = significantly different from group A,  $\beta$  = significantly different from group B. HCT - Hematocrit.

#### 4.4. Effect of AETO on red blood cell count

Figure 3 illustrates the effects of AETO on RBC count in the serum of rats with potassium bromate-induced hepatotoxicity. There was a significant increase ( $p < 0.05$ ) in the serum level of RBC in group D rats when compared with the normal control (group A). The serum level of RBC is also significantly different when comparing the treatment groups (C and D) with non-treated group (group B). There was a dose-dependent difference between the treated groups (C and D) when compared to each other.

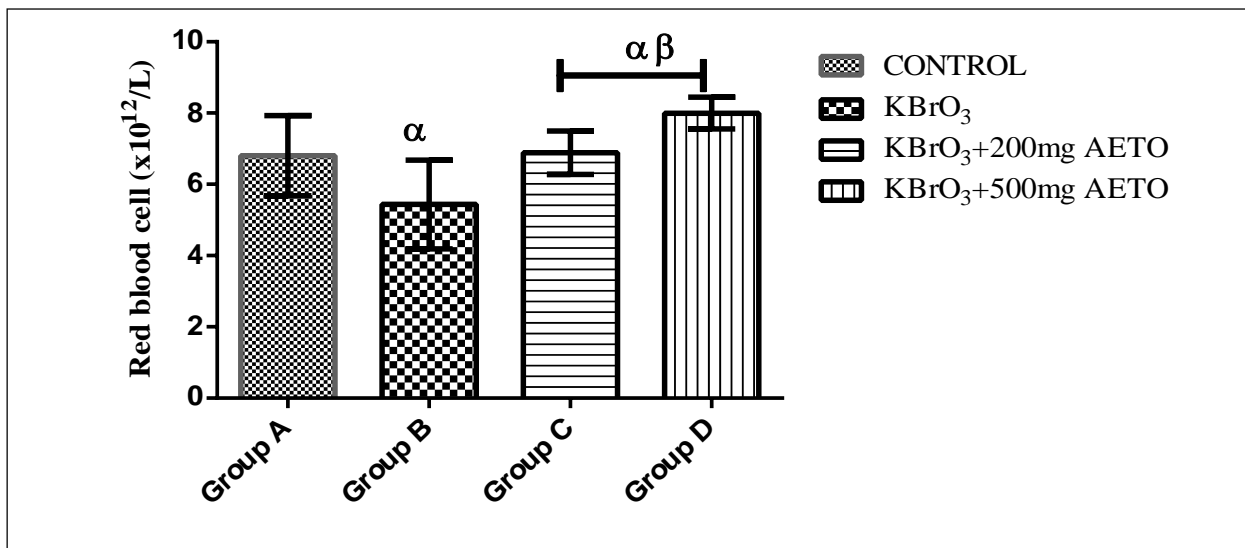


Figure 3: Effects of AETO on serum RBC count

**Note:** Value of  $p < 0.05$  was considered significant. The values with superscript  $\alpha$  = significantly different from group A,  $\beta$  = significantly different from group B. RBC – Red Blood Cell.

#### 4.5. Effect of AETO on white blood cell count

Figure 4 illustrates the effects of AETO on WBC count in the serum of rats with potassium bromate-induced hepatotoxicity. There was a remarkable increase in the serum level of WBC in group D rats when compared with the normal control (group A), although the difference was not statistically significant ( $p < 0.05$ ). The serum level of WBC is significantly decreased in group B rats when compared with the control group (group A). A significant difference was observed when comparing the treatment groups (C and D) with non-treated group (group B). There was a dose-dependent difference between the treated groups (C and D) when compared to each other.

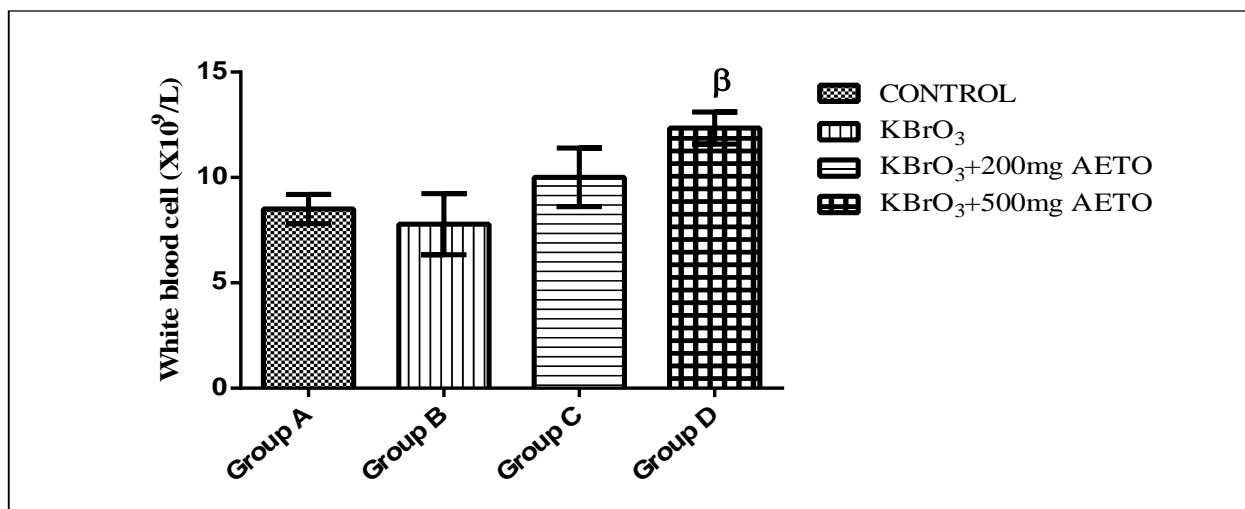


Figure 4: Effects of AETO on serum RBC count

**Note:** Value of  $p < 0.05$  was considered significant. The values with superscript  $\alpha$  = significantly different from group A,  $\beta$  = significantly different from group B. WBC – White Blood Cell.

#### 4.6. Effect of AETO on mean corpuscular volume

Figure 5 illustrates the effects of AETO on MCV in the serum of rats with potassium bromate-induced hepatotoxicity. There was no significant difference ( $p < 0.05$ ) in the serum level of MCV among rats in the treatment groups (C and D) when compared with the normal control (group A). The serum level of MCV is also not significantly altered when comparing the treatment groups with non-treated group (B).

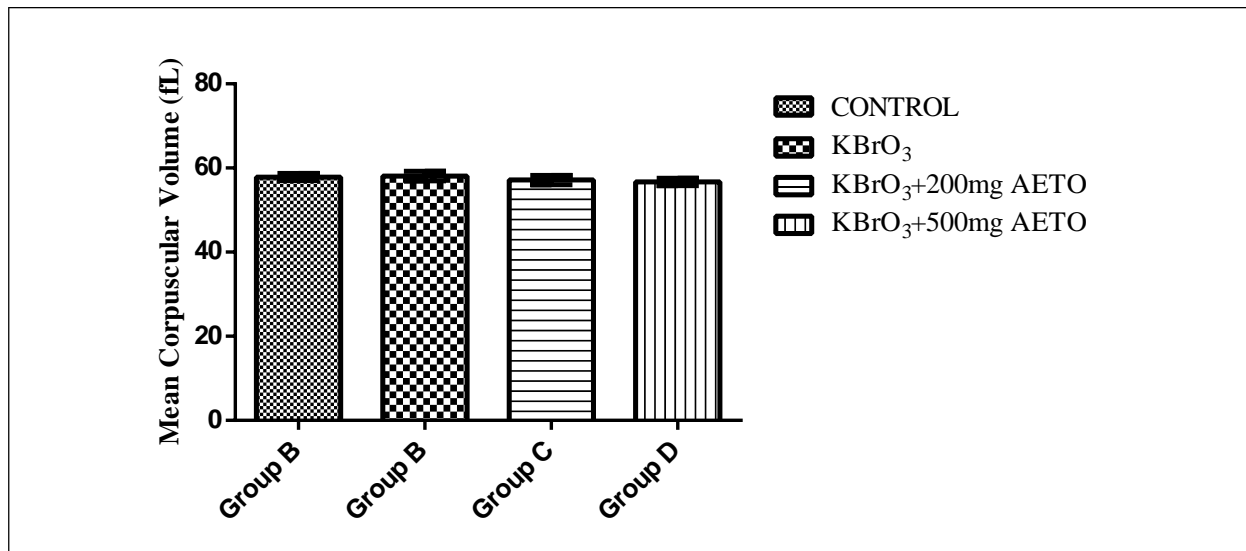


Figure 5: Effects of AETO on serum MCV

**Note:** Value of  $p < 0.05$  was considered significant. The values with superscript  $\alpha$  = significantly different from group A,  $\beta$  = significantly different from group B. MCV – Mean Corpuscular Volume.

#### 4.7. Effect of AETO on mean corpuscular hemoglobin concentration

Figure 6 illustrates the effects of AETO on MCHC in the serum of rats with potassium bromate-induced hepatotoxicity. There was a significant decrease ( $p < 0.05$ ) in the serum level of MCHC in group B rats when compared with the normal control (group A). The serum level of MCHC was also significantly decreased when comparing group (D) with non-treated group (group B).

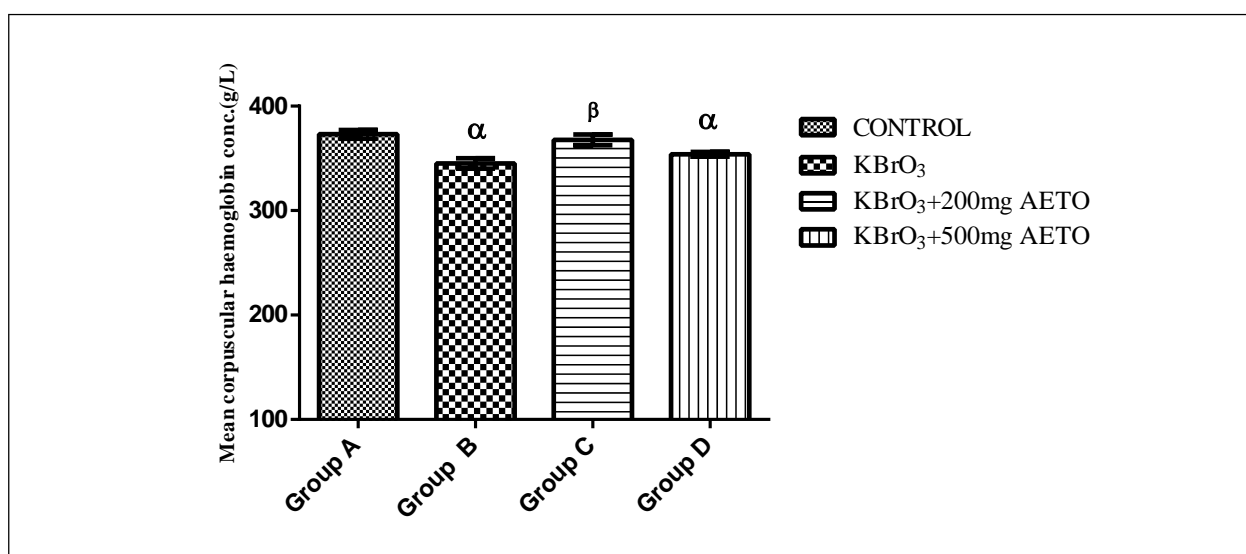


Figure 6: Effects of AETO on serum MCHC

**Note:** Value of  $p < 0.05$  was considered significant. The values with superscript  $\alpha$  = significantly different from group A,  $\beta$  = significantly different from group B. MCHC – Mean Corpuscular Hemoglobin Concentration.

#### 4.8. Effect of AETO on platelet count

Figure 7 illustrates the effects of AETO on PLT count in the serum of rats with potassium bromate-induced hepatotoxicity. There was a remarkable increase ( $p < 0.05$ ) in the serum level of PLT in the treated groups (C and D) rats when compared with the normal control (group A). The serum level of PLT is significantly decreased in group B rats when compared with the control group (group A). A significant difference was observed when comparing the treatment groups (C and D) with non-treated group (group B).

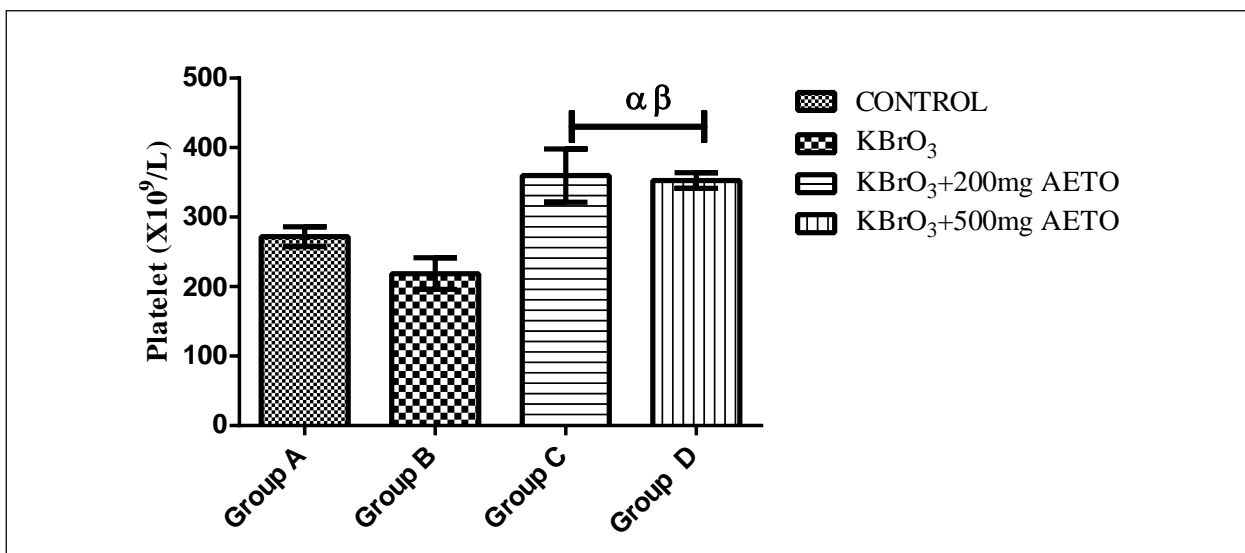


Figure 7: Effects of AETO on serum platelet count

Note: Value of  $p < 0.05$  was considered significant. The values with superscript  $\alpha$  = significantly different from group A,  $\beta$  = significantly different from group B. PLT - Platelet.

#### 4.9. Effect of AETO on lymphocyte

Figure 8 illustrates the effects of AETO on lymphocyte count in the serum of rats with potassium bromate-induced hepatotoxicity. There was a significant increase ( $p < 0.05$ ) in the serum level of lymphocytes in group D rats when compared with the normal control (group A). The serum level of lymphocyte was significantly

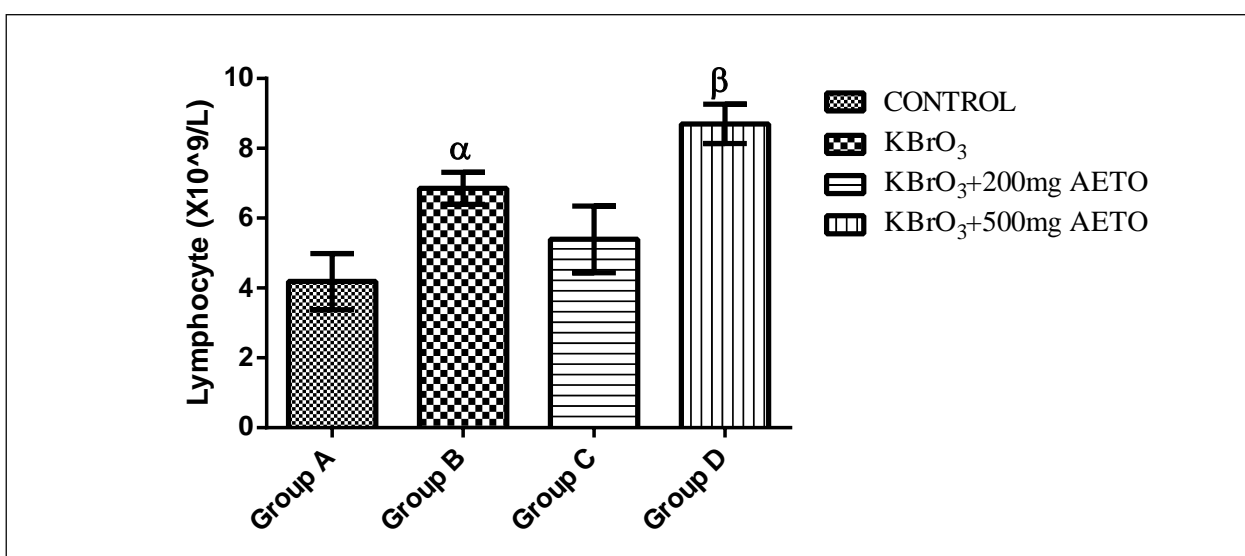


Figure 8: Effects of AETO on serum lymphocyte count

Note: Value of  $p < 0.05$  was considered significant. The values with superscript  $\alpha$  = significantly different from group A,  $\beta$  = significantly different from group B. LYMPH - Lymphocytes.



increased in group B rats when compared with the control group (group A). A significant difference was observed when comparing the treatment group (D) with non-treated group (group B). There was a significant dose-dependent difference between the treated groups (C and D) when compared to each other.

## 5. Discussion

This present study showed that administration of AETO enhances weight gain among rats as evident in the significant increase in the percentage weight gain of the rats in the treated groups (C and D) when compared with the normal control group (A). This could be as a result of the inhibitory effect of *Telfairia occidentalis* on the growth of intestinal microbes such as *E. coli*, *S. typhi*, *Strept. Faecalis* (Obboh et al., 2006; and Oyewole and Abalaka, 2012) leading to an increased intestinal absorption of digested foods thereby enhancing gastrointestinal tract efficiency. The increased rat weight observed in this study can also be due to the rich nutrient content of *Telfairia occidentalis* leaf. However, the weight gain recorded in the group treated with potassium bromate ( $\text{KBrO}_3$ ) due to the low dose of  $\text{KBrO}_3$  used (DeAngelo et al., 1998). At higher doses, rat growth becomes retarded and the weight significantly reduced. This was probably due to the binding of  $\text{KBrO}_3$  to the iodine receptors, minimizing iodine uptake by thyroid gland and causing iodine insufficiency leading to growth retardation (WHO, 2007).

The administration of AETO for three weeks in the treated groups (C and D) showed normal liver tissue and normal architecture of the hepatic lobules which is nearly similar to that of the control group. Both aqueous and ethanolic extracts of *Telfairia occidentalis* leaf have hepatoprotective properties, although the aqueous extract was more potent than the ethanolic extract, which could be related to the higher antioxidant activity of the aqueous extract (Obboh, 2005). Various researches (Obboh, 2005; and Bolaji and Olabode, 2011; and Danladi et al., 2012) have reported that the hepatoprotective activity of *Telfairia occidentalis* as a link with the high antioxidant property of the plant. The pathological responses of the liver tissue to  $\text{KBrO}_3$  observed in this among rats in group B were in agreement with that obtained by Oyewo et al. (2013) and Gibreel (2008), who reported hepatocyte degeneration, necrosis in liver, dilation of portal veins and sinusoidal dilatations. Vacuolation and sinusoidal dilatation of liver cells have been previously associated with reduction of antioxidant enzymes and enhancement of xanthine oxidase and lipid peroxidation of  $\text{KBrO}_3$ . Fibrosis was also observed in the rats administered with  $\text{KBrO}_3$ . Liver fibrosis is a catabolic feature associated with protein breakdown. These are various possible sources of collagen formation in the liver including; hepatocytes, fibroblasts, myofibroblasts and biliary epithelial cells (Phillips et al., 1987). In the protective groups (C and D), the histopathological findings revealed marked hepatoprotective effects of AETO. *Telfairia occidentalis* extracts possess potent antioxidant activities which could be derived from compounds such as flavonoids and polyphenols.

$\text{KBrO}_3$  is a very powerful oxidizer used as flour improver, strengthening the dough and allowing higher rising. It is an oxidizing agent, and under the right conditions, will be completely used up in the baking bread. However, if too much is used, or the bread is not cooked long enough or at a high enough temperature, then a residual amount will remain. As observed from this study, WBC and PLT counts were decreased in rats administered with  $\text{KBrO}_3$  in water. The decreased in WBC count was in accordance with the work of Thompson and Westfall (1949), who reported a decrease of leucocyte count from  $15,500/\text{mm}^3$  to  $9,600/\text{mm}^3$  in a two and a half year old boy in a period of two months after swallowing a half glass of neutralizer containing  $\text{KBrO}_3$ . Decreased leucocyte count has also been reported due to consumption of chemical like bromate. The reduction in WBC and PLT counts could be due to the DNA strand breakage in these cells induced by the oxidative stress associated with  $\text{KBrO}_3$  (Chipman et al., 1988; Thompson and Westfall, 1949; and Sai et al., 1992). Furthermore, there could have been bone marrow suppression with selective megakaryocyte depression (Hoffbrand et al., 2004). On the other hand it could be that  $\text{KBrO}_3$  has a direct damaging effect on the platelets. The increased level of lymphocyte showed lymphocytosis in rats administered with  $\text{KBrO}_3$ , which could be due to the depletion of the intracellular GSH by the diethylmaleate in lymphocytes, which decreases the amount of strand breakage induced by potassium bromate (Parson and Chipman, 2000).

It was also observed from this study that AETO caused significant increases in WBC count, RBC count, PLT count, lymphocyte count, and HCT concentration. The increase in the haematological indices observed in this study is in agreement with the observations made by Obeagu et al. (2014) after feeding rats for one week with different concentrations (100 mg, 200 mg and 300 mg) of ethanol extracts of *Telfairia occidentalis* leaves. The chemical composition of the leaves might be connected with the increase in the haematological parameters observed in this study. The chemical composition of the leaves of *Telfairia occidentalis* had been shown to

include Vitamin A, proteins, Vitamin C, thiamine, riboflavin, fats, nicotinamide, and minerals such as zinc, iron, calcium and magnesium (Akubue et al., 1980; Kayode and Kayode, 2011; and Toma et al., 2015). Tindal (1968) and Fasuyi (2006) reported the amino acid profile of *Telfairia occidentalis* to contain alanine, glycine, glutamine, aspartate, cysteine, leucine, methionine, tryptophan, histidine, lysine, arginine, serine, threonine, valine, threonine, valine, tyrosine, isoleucine, and phenylalanine. Some of the components are well-known hemopoietic factors that have direct influence on blood production in the bone marrow. For example, iron is a well-known hemopoietic factor (Ganong, 2005). However, the amino acids derived from *Telfairia occidentalis* could be used for the synthesis of globin chains of the hemoglobin and this could also contribute to the increase in hemoglobin concentration.

This study established the assertion that AETO could improve haematological parameters as well as ameliorate the hepatotoxic effect of potassium bromate by restoring the normal histoarchitecture of the liver.

## 6. Conclusion

Based on the data from this study, it was observed that the AETO was very potent in preventing and repairing potassium bromate-induced hepatotoxicity in a rat model. It also establishes the assertion that AETO is an effective anti-oxidative agent. Continuous administration of AETO increases haematological parameters in Wistar rats therefore; its anti-anaemic property is ascertained. This study also confirms the hepatotoxic property of potassium bromate on Wistar rats. It also decreases blood parameters and rat weight only at higher doses.

## Recommendations

The effort to stop the use of potassium bromate in preparation of foods should be intensified. NAFDAC should also focus attention not only on bread, but on other bakery products in which flour is used as a raw material. The physical properties of  $KBrO_3$  make it easy to be taken or administered as a poison to human, thus its use and handling should be highly regulated by the relevant authorities. Further investigation is necessary to elucidate the mechanism of hepatotoxicity caused by potassium bromate.

*Telfairia occidentalis* which has been proven to be an anti-inflammatory, anticholesterolemic and antidiabetic farm product should be planted in the gardens and is recommended to be taken as food in very large quantities to boost blood production and fight anaemia.

## References

- Adaramoye, O. A., Achem, J., Akintayo, O. O. and Fafunso, M. A. (2007). Hypolipidemic effect of *Telfairia occidentalis* fluted pumpkin in rats fed a cholesterol-rich diet. *Journal of Medicinal Food*, 10(2), 330-336.
- Akubue, P. I., Kar, A. and Nnachetta, F. N. (1980). Toxicity of extracts of roots and leaves of *Telfairia occidentalis*. *Planta Med.* 38, 339-343.
- Bolaji, O. and Olabode, O. (2011). Modulating effect of aqueous extract of *Telfairia occidentalis* on induced cyanide toxicity in rats. *Nigeria Journal Physiological Science*, 26(2), 185-191.
- Chipman, J. K., Davies, J. E., Parson, J. L., O'Neill, G. and Fawell, J. K. (1988). DNA Oxidation by Potassium Bromate; a Direct Mechanism or Link to Lipid Peroxidation?. *Toxicology*, 126, 93-102.
- Danladi, J., Abayomi, K.B. and Dahiru, A. U. (2012). Comparative study of the hepatoprotective effect of ethanolic extract of a *Telfairia occidentalis* (Ugu) leaves and silymarin on paracetamol-induced liver damage in Wistar rats. *International Journal Animal Veterinary Advances*, 4(4), 235-239.
- DeAngelo, A. B., George, M. H., Kilburn, S. R., Moore, T. M., Wolf, D. C. (1998). Carcinogenicity of potassium bromate administered in the drinking water to male B6C3F1 mice and F344/N rats. *Toxicological Pathology*. 26(5), 587-594.
- Dimkpa, U., Ukoha, U. U., Anyabolu, E. A., Uchefuna, R. C., Anikeh, L. C., Oji, O. J., Besong, E. E. and Emenjo, O. A. (2013). Hepatotoxic effects of potassium bromate on adult Wistar rats. *Journal of Biology, Agriculture and Healthcare*, 3(7), 111-115.
- Dixit, S. and Ali, H. (2010). Antioxidant potential some medicinal plants of central India. *Journal for Cancer Therapy*, 1, 87-90.
- Eseyin, O.A., Igboasoiyi, A.C., Oforah, E., Nkop, N. and Agboke, A. (2005). Hypoglycaemic activity of *Telfairia occidentalis* in rats. *Journal of Pharmacology and Bioresources*, 2, 36-42.
- Fasuyi, A. O. (2006). Nutritional potentials of some tropical vegetable leaf meals: chemical characterization and functional properties. *African Journal of Biotechnology*, 5, 49-53.

- Ganong, W. F. (2005). *A review of medical physiology. Appleton and Lange*, 496.
- Gibreel, H. M. (2008). *Toxicity of potassium bromate to Nubian goat kids*. M V Sc. Thesis, Faculty of Veterinary Medicine, University of Khartoum.
- Halliwell, B. and Gutteridge, J. M. (1989). *Free radicals in biology and medicine*. Clarendon press, Oxford.
- Hamzah, R. U., Jigam, A. A., Makun, H. A. and Egwim, E. C. (2013). *Antioxidant properties of selected african vegetables, fruits and mushrooms: A review*. DOI: 10.5772/52771. Dimensions ID: pub.1050457688 Available at <http://www.intechopen.com/books/antioxidant-properties-of-selected-africanvegetables-fruits-and-mushrooms-a-review>.
- Hoffbrand, A. V., Petit, J. E. and Moss P. A. H. (2004). *Essential haematology* (4th ed., pp. 252-253). Oxford: Blackwell.
- Kayode, A. A. A. and Kayode, O. T. (2011). *Some medicinal values of Telfairia occidentalis: A review. American Journal of Biochemistry and Molecular Biology*, 1, 30-38.
- Mosha, T. C. and Gaga, H. E. (1999). *Nutritive value and effect of blanching on trypsin and chymotrypsin inhibitor activities of selected leafy vegetables. Plant Foods for Human Nutrition*, 54, 271-283.
- National Research Council (NRC) (2011). *Guide for the care and use of laboratory animals* (8th Ed.). The National Academies Press.
- Nwanna, E. E. and Oboh, G. (2007). *Antioxidant and hepatoprotective properties of polyphenol extracts from Telfairia occidentalis (fluted pumpkin) leaves on acetaminophen induced liver damage. Pakistan Journal of Biological Sciences*, 10(16), 2682-2687.
- Obeagu, E. I., Chikelu, I. M., Obarezi, T. N., Bernice, N. and Anaebo, Q. B. (2014). *Haematological effects of fluted pumpkin (Telfairia occidentalis) leaves in rats. International Journal of Life Sciences, Biotechnology & Pharmaceutical Research*, 3(1), 2250-3137.
- Oboh, G., Nwanna, E. E. and Elusiyan, C. A. (2006). *Antioxidant and antimicrobial properties of Telfairia occidentalis (Fluted pumpkin) leaf extracts. Journal of Pharmacology and Toxicology*, 1, 167-175.
- Oboh, G. (2005). *Hepatoprotective property of ethanolic and aqueous extracts of fluted pumpkin Telfairia occidentalis leaves against garlicinduced oxidative stress. Journal of Medicinal Foods*, 8, 560-563.
- Oyewo, O. O., Onyije, F. M. and Awoniran, P. O. (2013). *Hepatotoxic effect of potassium bromate on the liver of wistar rats. Journal of Morphological Science*, 30(2), 107-114.
- Oyewole, O. A. and Abalaka, M. E. (2012). *Antimicrobial activities of Telfairia occidentalis (fluted pumpkins) leaf extract against selected intestinal pathogens. Journal of Health Science*, 2(2), 1-4. DOI: 10.5923/j.health.20120202.01
- Parsons, J. L. and Chipman, J. K. (2000). *The role of glutathione in DNA damage by potassium bromate in vitro. Mutagenesis*, 15(4), 311-316.
- Phillips, M. I., Poucell, S., Patterson, J. and Valencia, P. (1987). *The liver. An atlas and text of ultrastructural pathology*. p. 398. New York: Raven Press.
- Sai, K., Uchiyama, S., Ohno, Y., Hasegawa, R. and Kurokawa, Y. (1992). *Generation of active oxygen species in Vitro by the interaction of potassium bromate with rat kidney. Cell Carcinogenesis*, 13, 333-339.
- Thompson, H. C. and Westfall, S. W. (1949). *Potassium bromate poisoning. Report of a case due to ingestion of a cold wave neutralizer. J. Paed.* 34, 362-364.
- Toma, I., Victory, N. C. and Kabir, Y. (2015). *The effect of aqueous leaf extract of fluted pumpkin on some hematological parameters and liver enzymes in 2, 4-dinitrophenylhydrazine induced anemic rats. African Journal of Biochemistry Research*, 9, 95-98.
- WHO (2007). *Evaluation of certain food additives and contaminants*. Geneva: WHO Press.

**Cite this article as:** Busuyi Kolade Akinola, Toluwase Solomon Olawuyi and Adesua Emmanuel Ogunmokinwa (2020). *The protective effects of Telfairia occidentalis on potassium bromate induced hepatotoxicity in adult Wistar rats. African Journal of Biological Sciences*. 2(3), 51-61.