




African Journal of Biological Sciences



Research Paper

Open Access

Cervical Kyphosis Correction in Multiple Degenerative Cervical Disc Disease

Yasser Hassan El-Miligui¹, Wael Tawfik Koptan¹, Ahmed Maher Sultan¹, Salah Ahmed Mohamed Senosy²

(1)- Orthopaedic Surgery department, faculty of medicine, Cairo University.

(2)- Orthopaedic Surgery department, faculty of medicine, Al-Azar University- Assiut

Corresponding author: Salah Ahmed Mohamed Senosy.

Email: Salahsenosy8@gmail.com

Article History

Volume 6, Issue 2, April 2024

Received: 3 June 2024

Accepted: 10 July 2024

Published: 10 July 2024

doi:

10.48047/AFJBS.6.2.2024.1605-1617

Abstract: Background: Cervical kyphosis can occur secondary to various underlying etiologies including: advanced degenerative disease, iatrogenic, trauma, neoplasm, infection, and systemic arthritis, **Purpose:** This study aimed to compare the degree of cervical kyphosis correction between anterior and posterior approaches from clinical assessment, functional outcomes using VAS (Visual Analogue Scan) & NDI (Neck Disability Index) scores; radiological measurement's using modified Cobb method (mCM), complications and failure of correction of both anterior and posterior approaches. **Patient and methods:** This was a prospective randomized comparative study with a total number of forty consecutive patients diagnosed with either degenerative cervical kyphosis with radiculopathy or myelopathy undergoing either anterior cervical interbody discectomy and fusion or posterior laminectomy and lateral mass fixation using simple randomization as first 2 patients did anterior and second 2 patients do posterior surgery in Kasr Al Ainy hospital, Cairo University and Al Haram Hospital between August 2018 and March 2020, **Results:** There was a highly significant decrease in terms of VAS neck between preoperative and postoperative (at 1, 3, 6 months and at the one-year follow-up) measurements ($P < 0.001$) in both groups. **Conclusion:** both methods anterior and posterior approach are effective in treatment of multiple degenerative cervical disc disease accompanied by cervical kyphosis but anterior approach is better concerning sagittal alignment, degree of correction, blood loss, hospital stay, clinical and functional improvement and lower rate of correction loss but it carries a little bit higher rate of complications.

Keywords: Cervical Kyphosis; Degenerative Cervical Disc Disease; degenerative cervical disc.

Introduction

Cervical kyphosis can occur secondary to various underlying etiologies including: advanced degenerative disease, iatrogenic, trauma, neoplasm, infection, and systemic arthritis (e.g., Rheumatoid Arthritis, Ankylosing Spondylitis) (1).

The presentation of symptomatic cervical kyphosis typically includes neck pain. However, severe deformity resulting in spinal cord or nerve compression can lead to myelopathy and/or radiculopathy. With progressive cervical misalignment, additional impairments can occur including problems with horizontal gaze, cough, swallowing and respiration (2).

There are three surgical strategies for CK treatment: the anterior, posterior and combined procedures. The main point of debate is the choice between the anterior and the combined procedures (3).

Some surgeons prefer the anterior-alone approach. It is associated with lower rates of morbidity and mortality than the combined approach (4). Another point of view is to do posterior approach (5).

Other surgeons prefer the combined anterior and posterior approach rather than the anterior procedure alone especially in patients with postlaminectomy kyphosis (PLK) (6)

This study aimed to compare the degree of cervical kyphosis correction between anterior and posterior approaches from clinical assessment, functional outcomes using VAS (Visual Analogue Scan) & NDI (Neck Disability Index) scores; radiological measurement's using modified Cobb method (mCM), complications and failure of correction of both anterior and posterior approaches.

Patients and Methods

This was a prospective randomized comparative study with a total number of forty consecutive patients diagnosed with either degenerative cervical kyphosis with radiculopathy or myelopathy undergoing either anterior cervical interbody discectomy and fusion or posterior laminectomy and lateral mass fixation using simple randomization as first 2 patients did anterior and second 2 patients do posterior surgery in Kasr Al Ainy hospital, Cairo University and Al Haram Hospital between August 2018 and March 2020.

Group (A) 20 patients had anterior cervical interbody discectomy and fusion group (B) 20 patients had posterior laminectomy and lateral mass fixation.

Inclusion Criteria: Patients with symptomatic degenerative cervical disc disease between C3 and C7 with loss of cervical lordosis manifested by Neck or arm (radicular) pain and/or functional/neurologic deficit confirmed by imaging older than 18 years after failure of all methods of conservative treatment.

Exclusion Criteria: Non degenerative cervical kyphosis (traumatic, congenital, tumors and following posterior laminectomy), systemic or local infection, active rheumatoid arthritis or any other medical condition(s) that would represent an increase in surgical risk or interfere with normal healing, previous known allergy to the implant material, such as polyether ether ketone or titanium alloy, severe Osteoporosis, medically unfit for anesthesia and refuse surgery or follow up.

Preoperative protocol

History taking: Personal history included: name, gender, age, occupation, special habits of medical importance.

Presenting complaint: History of present condition evaluating the onset, course and duration of symptoms. Neurological symptoms with special reference to difficulty in walking, abnormal gait and repeated falls, fine hand movement (clumsy hand), neck pain and radiculopathy, other upper extremity sensory symptoms, bladder symptoms as precipitancy and retention.

Examination: The process of physical examination involved general examination and a systematic assessment for gait analysis, neck, upper and lower limbs.

Neck examination: range of motion assessment and restriction of movement, focal neck tenderness, any spinous process tenderness and presence of a positive l'hermitte sign. (L'hermitte's sign, sometimes called the Barber Chair phenomenon, is an electrical sensation that runs down the back and into the limbs. It can be elicited by bending the head forward).

Upper Limb & Lower Limb: Inspection: Muscle wasting (unilateral or bilateral, symmetrical or asymmetrical), -pathological fasciculation, muscle Tone: By passive flexion and extension of all joints, motor Power Examination, sensory Examination, reflexes and ankle Clonus.

Gait analysis: Difficulty in walking manifested in the form of broad based gait, shuffling gait and buckling of lower extremity while walking up small inclines.

Investigations: Standard laboratory investigations: Complete blood picture, liver and kidney functions tests, fasting blood sugar and coagulation profile. **Radiological investigations:** Preoperative antero-posterior and lateral radiographs of the cervical spine The Cobb angle based on drawing a line parallel to lower endplate C2 and drawing a line parallel to lower endplate C7; another line drawn perpendicular to the previous both lines and angle produced will be our Cobb angle.

The Cobb angle was be estimated preoperative and at follow up at 1st month, 3rd months, 6th months and 1 year to assess healing and solid bony fusion and degree of kyphosis correction and also degree of loss of correction.

-Preoperative MRI Scan of cervical spine was performed for all patients as it provides an excellent detailed overview. **Visual Analogue Scale (VAS):** A Visual Analogue Scale (VAS) is a measurement instrument that tries to measure a characteristic or attitude that is believed to range across a continuum of values and cannot easily be directly measured. **Neck Disability Index (NDI):** The NDI is a modification of the Oswestry Low Back Pain Disability Index. It is a patient-completed, condition-specific functional status questionnaire with 10 items including pain, personal care, lifting, reading, headaches, concentration, work, driving, sleeping and recreation.

Informed consent: Proper informed consents were taken from the patients preoperatively Details of surgical procedure including benefits and possible risks, complications and follow up protocol were explained to the patients and included in the consent. The patient also consented to be included in the study.

Surgical approaches:

Anterior approach: Image initially was taken using the fluoroscope for determination of the level of the incision. An anterolateral approach (Smith-Robinson) approach was done (transverse incision in single or double levels and longitudinal in three or more levels).

A subperiosteal dissection of the prevertebral fascia and longus colli muscles using an elevator should then be performed. Once the longus colli muscles had been elevated, the hand-held Cloward retractors may be placed directly underneath the longus colli muscles. At this point, the fluoroscope was used to identify the level with a spinal needle in a particular disc space (Fig. 1).

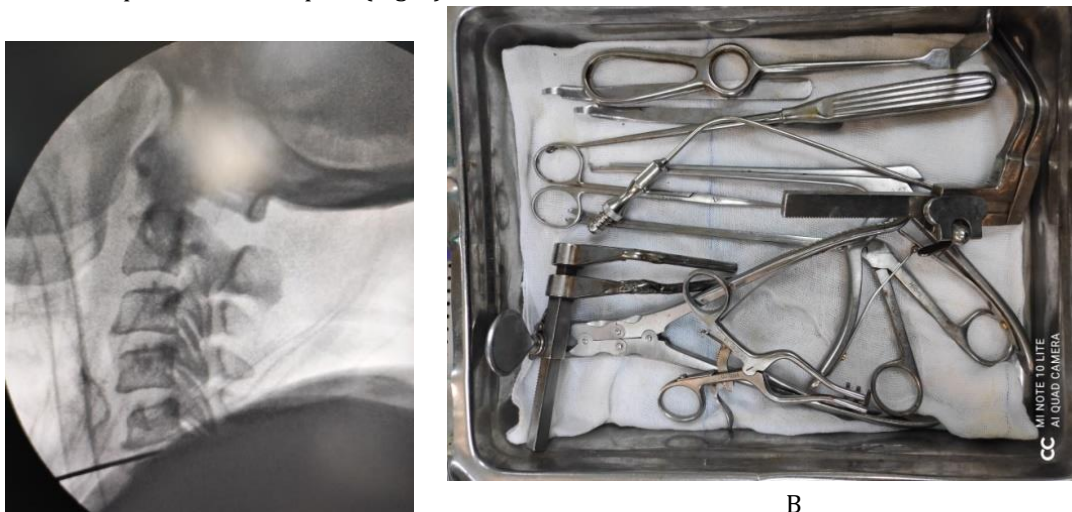

Figure (1): (A) Level determination by flouroscopy. (B) Instrumentation used.

The spaces were then measured by the trial fits. The appropriate cages were then placed in position and tapped into the disc spaces. A lateral view of the cervical spine was obtained using the fluoroscope in order to confirm adequate placement of each cage Fig. (2).

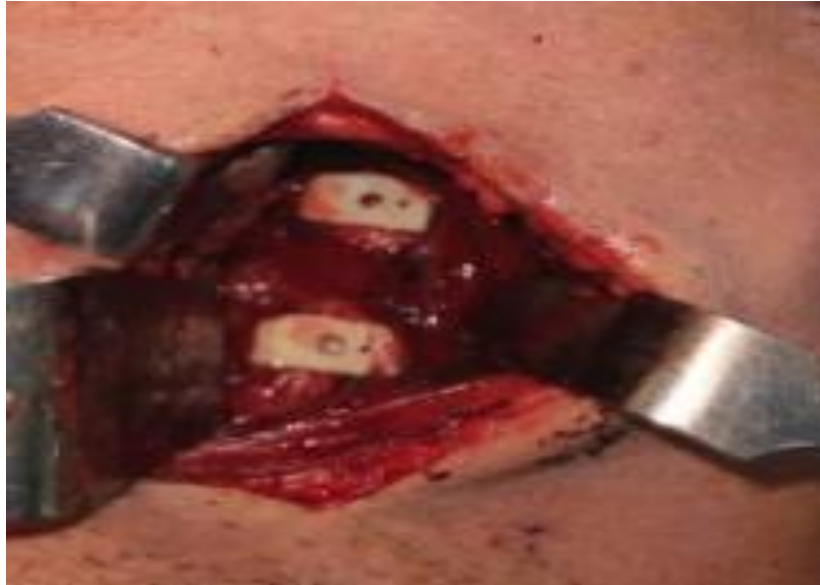

Figure (2): Intraoperative photo after cage insertion.

After removal of Casper pins we started to close the wound by putting a suction drain (size 12 or 14) at separate incision then started to close the subcutaneous tissues platysma muscle by interrupted suture then skin closure done by subcuticular sutures.

Posterior Approach: After endotracheal intubation, either the surgeon or experienced anesthesiologist was charged with controlling head position during the transition to the prone position. The arms were gently tucked to side, and shoulders may be taped distally when distal levels of the cervical spine will be exposed or when the neck was short or bulky fat pad was present or obstructs access. Fluoroscopic imaging or X-ray was done when extending to the distal cervical levels. The incision was carried down sharply through the dermis, and then electrocautery is usually used to expose the spinous process in the midline (fig. 3).

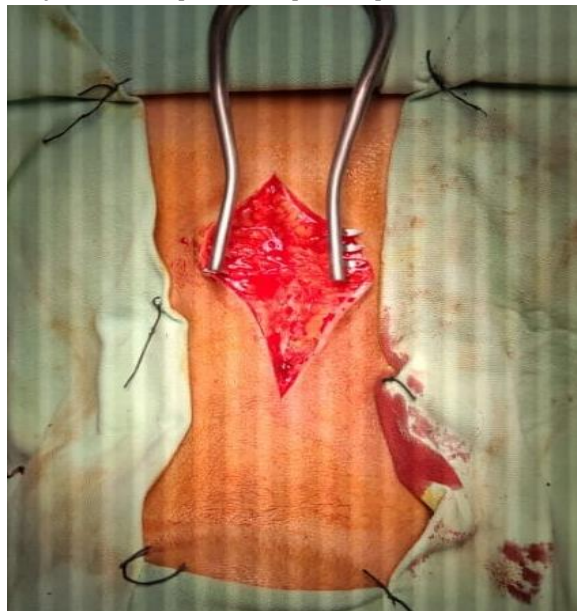

Figure (3): Skin incision in posterior cervical approach.

All polyaxial screw/rod constructs were used adequately in the subaxial region. Screws of 12-14 mm length and 3.5 mm width were usually used for fixation in most cases. Intraoperatively, each screw position was assessed separately by imaging guidance before the final placement.

Postoperative protocol: The patients were placed in a rigid Philadelphia collar for 1.5 months I.V antibiotic (Ceftriaxone 1gm) every 24 hours for 3 days postoperative and assessment of analgesic requirement. Stitches removed 2 weeks postoperative. Post-operative radiograph was done on the first postoperative day in AP and lateral views.

The patients were allowed to be up out of bed later on the day of surgery or the next morning. The drain was removed on the first to 3 days postoperative day. Patients were discharged from the hospital 3 to 5 days after the operative procedure if the general and neurological condition is stable.

Follow up:

Clinical follow up: Pain and disability will be assessed by NDI, VAS and MJOA on 1, 3, 6, 9 and 12 month intervals.

Radiological follow up: Serial postoperative radiographs on 1, 3, 6, 9 and 12 month Fusion was assessed by X-ray we apply the x-rays photo on surgimap application Fusion was considered successful if plain radiograph demonstrated confirmed by fusion criteria at one year follow.

We used the Modified Brantigan& Steffee criteria for anterior cervical fusion (146, 147,148).

Statistical analysis: Statistical analyses were performed using SPSS 16.0 statistical software (SPSS Inc., Chicago, IL, USA). The radiological and clinical values were expressed as means + standard deviations. A p-value <0.05 was considered statistically significant and that <0.001 was considered highly significant.

Results

In this prospective comparative randomized study, we treated 40 patients diagnosed as cervical kyphosis in multiple degenerative cervical disc disease and indicated for surgical intervention after failure of all conservative management. Half of them were treated by multilevel anterior cervical discectomy fusion (ACDF) (group I) and the other half treated by using posterior laminectomy and lateral mass fixation (group II).

In group I there were 6 females and 14 males with a mean age of 66.13 ± 9.76 SD, while in group II there were 5 females and 15 males with a mean age of 65.9 ± 8.05 SD, the P value was insignificant. table (1).

Table (1): Demographic data in the two studied groups

Items		Group				p value
		Group I (N=20)		group II (N=20)		
Age mean± SD		66.13 ±9.76		65.9 ±8.05		0.737#
		N	%	n	%	
Gender	Male	14	70.0%	15	75.0%	0.766*
	Female	6	30.0%	5	25.0%	
Number of levels involved	2 levels C3-4-5(3cases) C4-5-6(2cases) C3-4 C6-7(1case)	6	30.0%	6	30.0%	0.949*
	3 levels C3-4-5-6(6) C4-5-6-7(3) C3-4-5C6-7(3)	10	50.0%	8	40.0%	
	4 levels C3-4-5-6-7(4)	4	20.0%	6	30.0%	

P-value is insignificant.

The mean operative time in group II was 81.45 ± 20.13 SD minutes, and was highly significantly shorter than group I, which was 105.16 ± 35.87 SD minutes ($P < 0.001$) Table (2). Concerning of blood loss; in group I (300-900) ml it estimated mean of 466.00 ± 140.9 SD ml and in group II (750-1400) ml it estimated mean of 1081.89 ± 200.98 SD ml so P value is significant ($p=0.013$) Table (3) fig. (54). The mean hospital stays in group I Range (2-4) was 3.41 ± 0.98 SD days while in group II Range (3-6) was 5.34 ± 0.95 SD so P value is highly significant here ($P < 0.001$) Table (2).

Table (2): Show operative time, blood loss and length of hospital stay.

Items	Group		p value
	Group I (N=20)	Group II (N=20)	
Operative time (min.)	Range (60-160min) 105.16 ± 35.87 SD	Range (60-120) 81.45 ± 20.13 SD	<0.001 ##
Blood loss (ml)	Range (300-900) 466.00 ± 140.9 SD	Range (750-1400) 1081.89 ± 200.98 SD	0.013##
Hospital stay (days)	Range (2-4) 3.41 ± 0.98 SD	Range (3-6) 5.34 ± 0.95 SD	<0.001 ##

P value is significant (<0.05).

P value is highly significant (<0.01).

The mean neck VAS score in group I was 6.47 ± 0.82 SD preoperative, improved to 3.73 ± 0.69 SD at 1 months postoperative, and improved to 2.83 ± 1.29 SD at 3 months postoperative, And to 1.90 ± 0.96 SD at 6 months postoperative, finally to 1.40 ± 0.89 SD at the one-year follow-up . while in group II mean neck VAS score was in group 6.20 ± 1.35 SD preoperative, improved to 5.07 ± 0.83 SD at 1 months after surgery, improved to 4.57 ± 0.90 SD at 3 months postoperative, And to 3.47 ± 0.73 SD at 6 months postoperative and to 2.97 ± 1.0 SD at the one-year follow-up. There was a highly significant decrease in terms of VAS neck between preoperative and postoperative (at 1, 3, 6 months and at the one-year follow-up) measurements ($P < 0.001$) in both groups (Table 3).

Table (3): VAS neck in the two studied groups

Items	Group				P-value between groups#
	Group I (N=20)		Group II (N=20)		
	Mean	SD	Mean	SD	
Pre-op	6.47	0.82	6.20	1.35	0.708
1-month post-op	3.73	0.69	5.07	0.83	<0.001
3-month post-op	2.83	1.29	4.57	0.90	<0.001
6-month post-op	1.90	0.96	3.47	0.73	<0.001
12-month post-op	1.40	0.89	2.97	1.00	0.016
P- value for within groups, time effect \$	<0.001		<0.001		

P value is significant (<0.05).

P value is highly significant (<0.01).

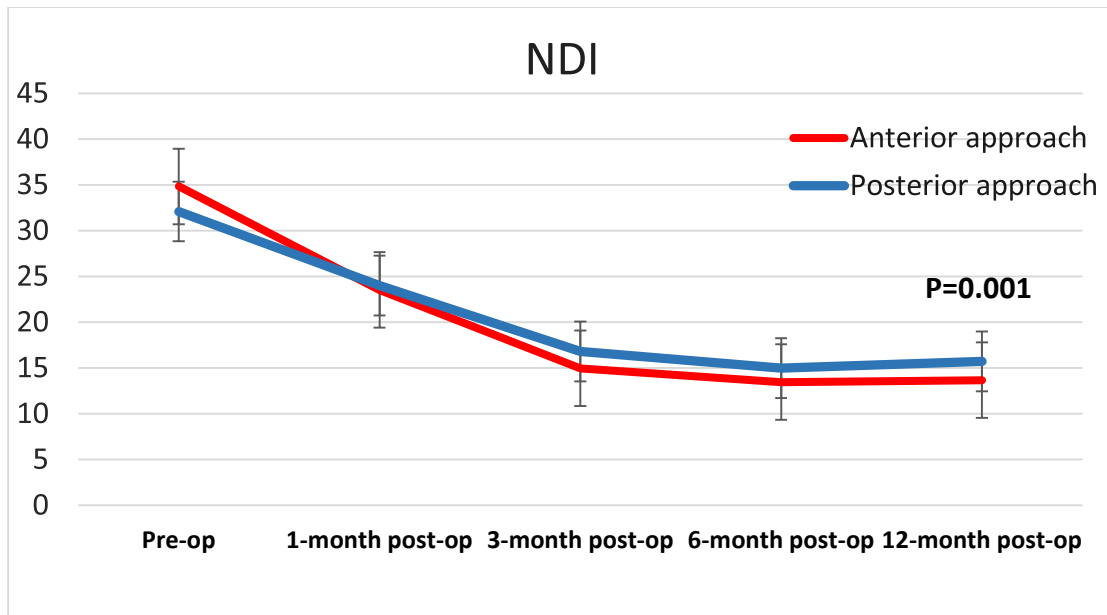


Figure (4): NDI in the study groups

There was non-significance difference $P > 0.05$ between both groups at different times except after 3 months $P < 0.05$. There was highly significance difference $P < 0.000$ regarding to significance difference between baseline and different times in each group (fig. 4).

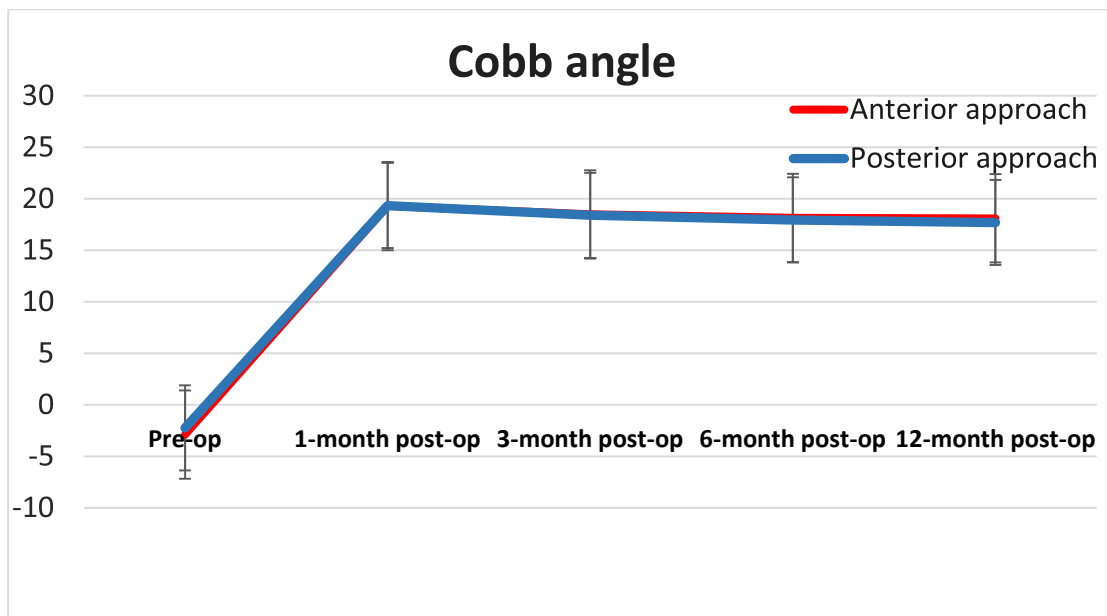


Figure (5): Cobb angle in the study groups.

The degree of loss of correction is due to cage subsidence or early adjacent segment in group I and weak purchase of lateral mass screw or also early adjacent segment. Loss of correction is more in Group II -1.6 more than Group I -1.2 as shows in (fig.5).

Fusion rate in the group I was present in 7 of 20 cases (35%) by 3th month, 15 of 20 cases (75%) by 6th month and 17 of 20 cases (85%) by one year 3 cases had delay fusion or metal failure. In the group II, fusion was present in 5 of 20 cases (25%) by 3th month, 11 of 20 cases (55%) by 6th month an in 15 Of 20 cases (75%) by one year and 5 cases showed delayed union more than one year or metal failure (Table 4).

Table (4): Radiological assessment of fusion in the two studied groups

Item		Group				p value
		Group I (N=20)		group II (N=20)		
		N	%	n	%	
Complete fusion	3-month post-op	7	35.0%	5	25.0%	0.490*
	6-month post-op	15	75.0%	11	55.0%	0.525*
	12-month post-op	17	85.0%	15	75.0%	0.519*
Non union	After 12 months	3	15.0%	5	25.0%	

There were four patients (20%) in group I and only one patient in group II (5%) (Difficult intubation) complained of dysphagia, which resolved spontaneously by 1-2 weeks. In group I we have a three cases with nonunion (15%) till one year including two cases of asymptomatic cage subsidence and one case with screw loosening and revised while in group II we found a five cases with nonunion at one year (25%) including two cases with metal failure with no neurological complication we revise one case and the others refuse the second surgery.

Table (5): Complications in the two studied groups

Item		Group				p value
		Group I (N=20)		group II (N=20)		
		N	%	n	%	
Complication	Dysphagia	4	20.0%	1	5.0%	0.874*
	Dural tear	1	5.0%	3	15.0%	
	Hoarseness of voice	3	15.0%	1	5.0%	
	Recurrent laryngeal nerve injury	1	5.0%	0	0.0%	
	C5 radiculopathy	0	0.0%	2	1.0%	
	postoperative hematoma	0	0.0%	1	0.0%	
	Wound infection	1	5.0%	0	0.0%	
	Nonunion at one year	3	15.0%	5	25.0%	
	Metal failure	1	5.0%	2	10.0%	
	Revision surgery	1	5%	1	5%	

Case presentation:

Female patient, 53 years old smoker, presented with 11 months history of upper limb bilateral brachialgia (Left>Right). She had difficulty in performing daily hand activity and gait disturbance walking with a stick. She had hypoesthesia over both upper limbs (left>Right). Upper motor neuron symptoms positive Babinski and generalized hyperreflexia with gait disturbance. Plain X-rays and MRI revealed C4-5, C5-6 and C6-7 central prolapsed cervical disc with high cord signal opposite C4-5-6-7 level. Operation was done in 2nd of October 2018, with three levels ACDF, operative time was about 90 minutes and hospital stay was 3days.

-VAS of Neck pain improved from 8 to 2 at 6 months and improved to 0 at 1year, VAS of upper limb pain from 9 to 3 at 6 months and decreased to 2 at 1year. NDI from 25 to 15 at 3 months and to 14 at 1year. mJOA improved from 11 preoperative to 15 at 6 months and maintained at 15 till one year, Cobb angle improved from -7.1° preoperative to 24° 1 month, and 22.4° at 3 months postoperative and 20° at 6 months and maintained at 20° at 1 year. Fusion completed at 1 year.

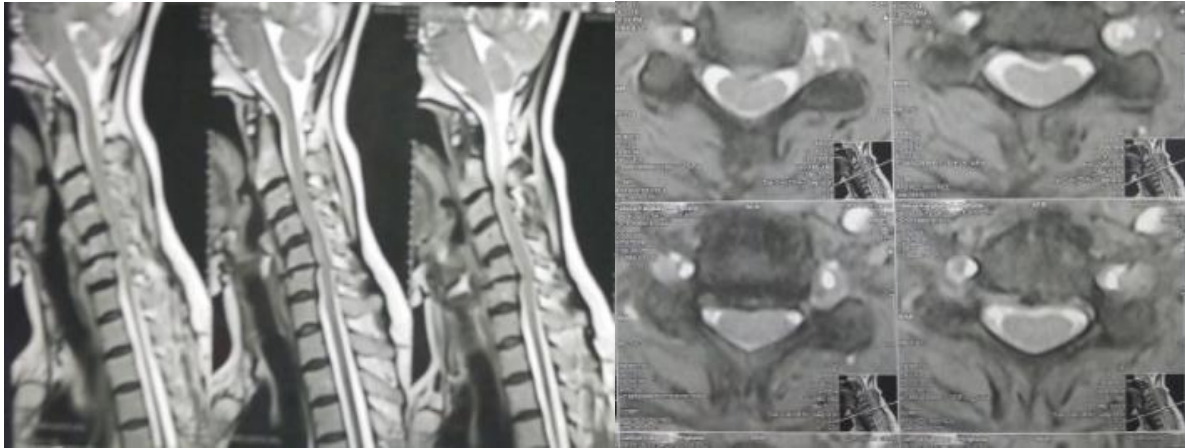


Figure (6): Preoperative MRI sagittal and axial section with cord myelopathy.

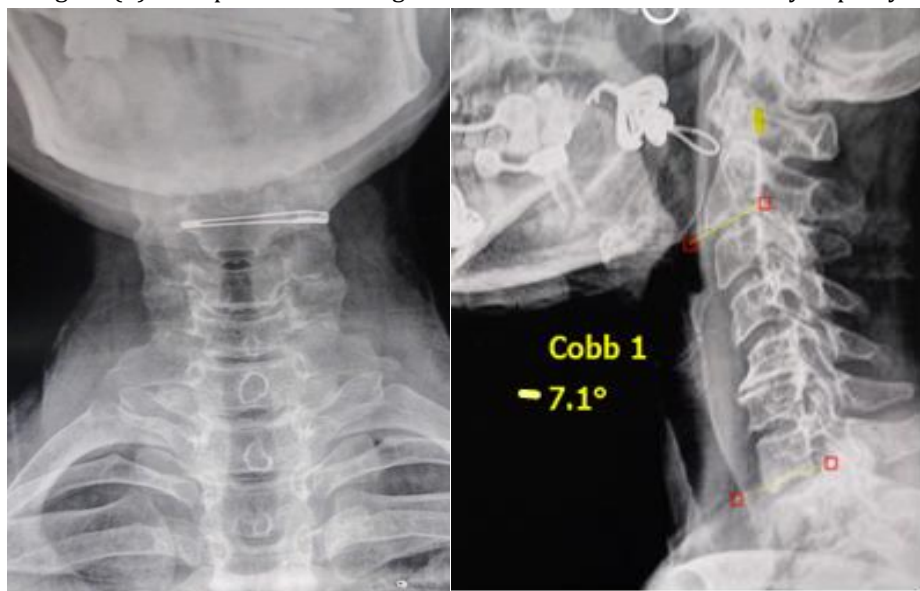


Figure (7): Preoperative X-rays AP and lateral view Cobb angle was -7.1° .

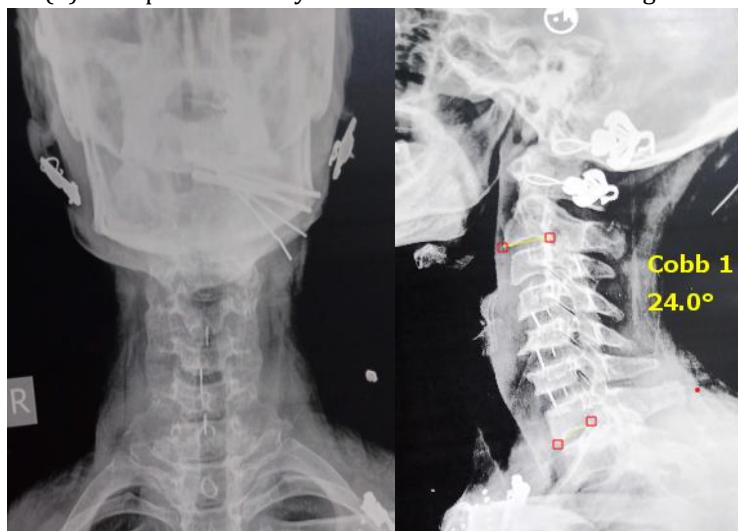


Figure (8): Postoperative X-ray AP and lateral view at 1 month with Cobb angle 24° .

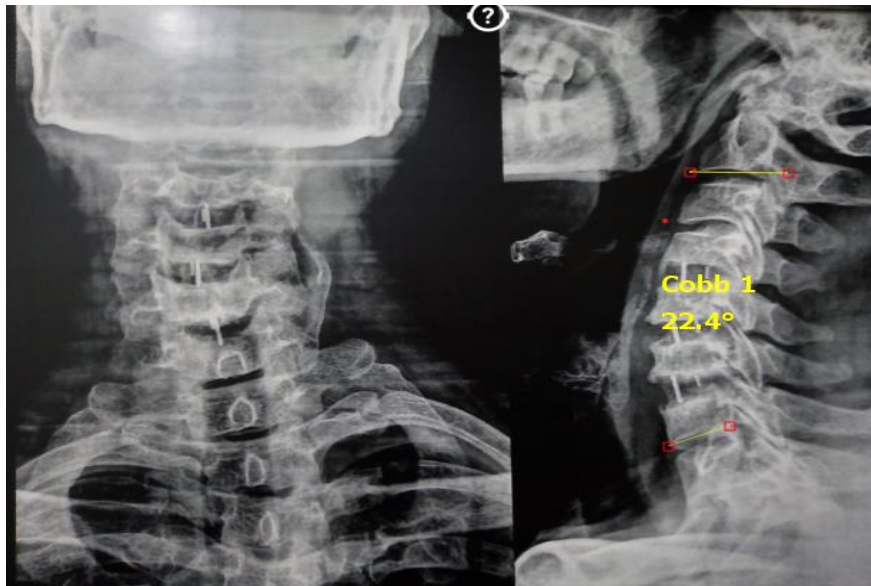


Figure (9): Postoperative X-ray AP and lateral view at 3 months Cobb angle 22.4°.

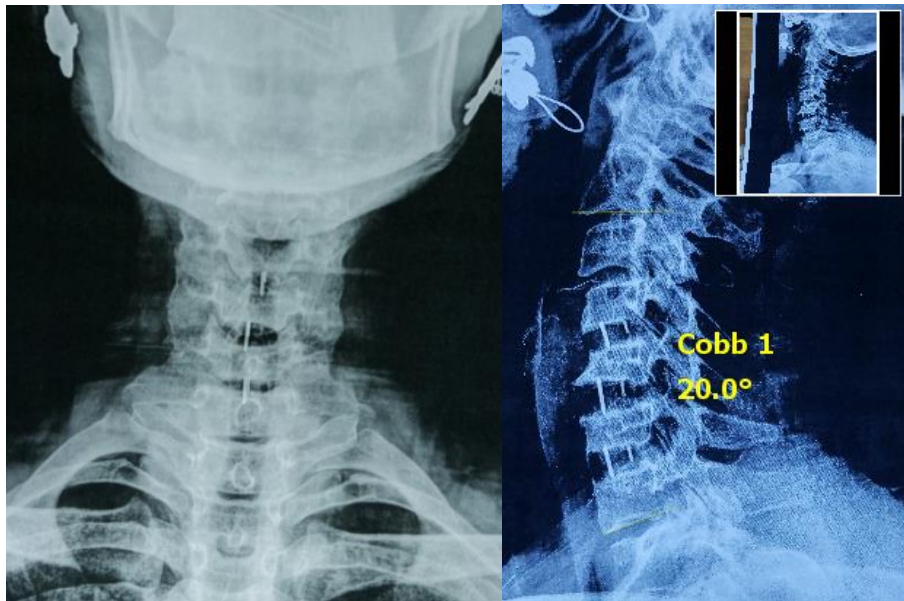


Figure (10): Postoperative X-ray AP and lateral view at 6 months Cobb angle 20°.

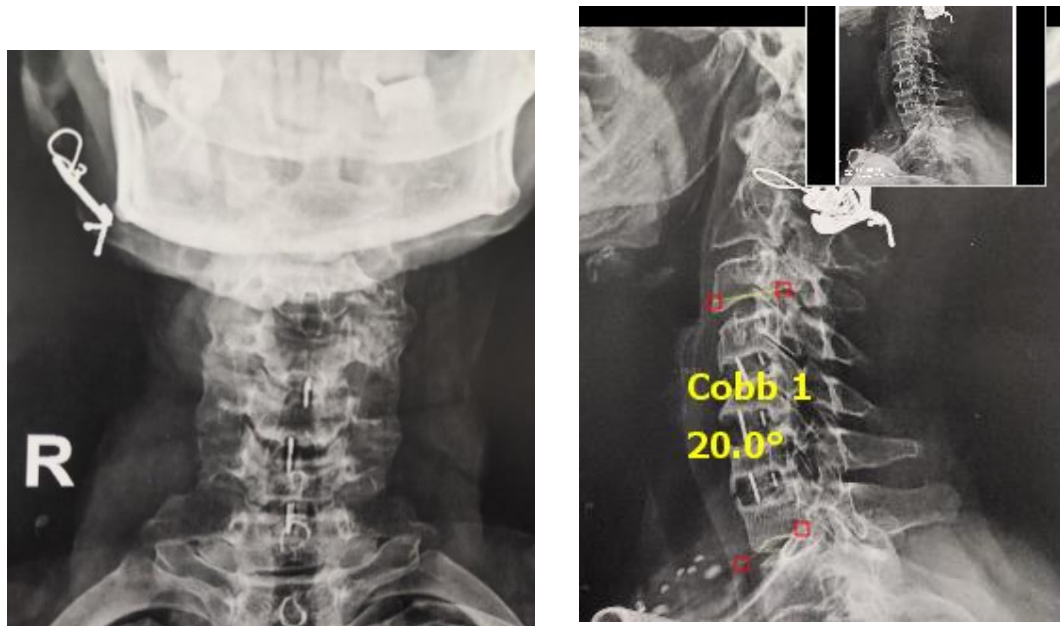


Figure (11): Postoperative X-ray AP and lateral view of 1 year Cobb angle 20°.

Discussion

In the present study, our main goal was to compare the clinical outcomes, postoperative kyphosis correction, rate of fusion and complications between anterior and posterior approaches for the treatment cervical kyphosis in multiple degenerative cervical disc disease.

The study was carried out in Kasr Al Ainy hospital, Cairo University and Al Haram Hospital, Cairo, Egypt. After informed consent, A Prospective, randomized study started by 40 degenerative cervical kyphosis patients were assigned into two groups, 20 in each group, then evaluated as regards their patient characteristics, operative data, neck VAS score, upper limb VAS score, mJOA scale, NDI, and Cobb angle correction and timing of fusion and complications.

Patients were divided into two groups; Group I: included 20 patients performed the multilevel anterior cervical discectomy & fusion (ACDF). Group II: included 20 patients performed the posterior laminectomy with lateral mass fixation.

We describe the results of demographic data were compared between the 2 groups. It was found that no significant differences between two groups in age (years), number of levels affection and gender.

In the current study, mean age of presentation was more than 60 years. These results corroborate the ideas of **Al-Ryalat, et al., (7)** who suggested that symptoms of cervical degeneration kyphosis found most commonly in individuals aged 40-60 years. Radiologic changes increase with patient age; 70% of asymptomatic persons older than 70 years have some form of degenerative change in the cervical spine.

Regarding gender we were noted that there was a significant decrease in presentation for surgical treatment in female group in comparison to their male counterpart in the same age group. This might be an additional contributing effect to the final outcome. These results corroborate the ideas of **El-Ghandour, et al., (8)**. Who reported that majority of patients (41/65) were male individuals.

According to operative evaluation findings of our study, operative time (min.) was significantly decreased in anterior approach group than in posterior approach group. However, the mean hospital length of stay was significantly longer in the posterior group compared to the anterior group.

The adverse results by **El-Ghandour, et al., (8)** who found that operative time was shorter in the posterior approach group (62.7 ± 9.2 SD vs 33.5 ± 6.8 SD) ($P = 0.001$) and the mean hospital length of stay was significantly higher in the posterior group (5.2 ± 2.4 SD days) vs (3.5 ± 1.4 SD days) $P < 0.001$. Also.

El-Ghandour, et al., (8) reported that the VAS neck score at 12 months after operation was 2.6 ± 1.7 SD in the anterior approach group and 3.7 ± 2.1 SD in the posterior approach group ($P < 0.05$). The VAS neck score had improved from baseline by 2.4 ± 2.6 SD in the anterior approach group and by 0.6 ± 2.4 SD in the posterior approach group ($P < 0.05$). This is not similar to the results reported by **Kristof, et al., (9)** who showed no statistically significant difference in the VAS score between two group.

Beside, we observed an overall significant improvement in the NDI in both groups, which was significantly better in the anterior approach group. From this results by **El-Ghandour, et al., (8)** showed that the mean NDI at 1 year after surgery was 13.6 ± 5.7 SD in the anterior decompression group and 17.5 ± 6.3 SD in the posterior decompression group ($P < 0.05$).

A non-randomized randomized controlled trial comparing ACDF (JOA 13.2) vs laminectomy (JOA 13.67) in 52 patients with multi-level CSM demonstrated that both approaches showed significant improvement in JOA score ($P < 0.001$) **Zaveri and Jaiswal, (10)**.

Our study demonstrated that the preoperative segmental angle and C2–C7 Cobb angle were improved after ACDF ($P < 0.05$). A similar pattern of results was obtained in **Noh, et al., (11)** expectable that the segmental and C2–C7 Cobb angles at the final follow-up were markedly improved in the ACDF group compared to those at the preoperative assessment ($P < 0.05$).

The meta-analysis by **Shamji, et al., (12)** indicated that preoperative cervical alignment was enhanced after surgery via the anterior approach, and greater changes occurred after ACDF. This was because ACDF can support more distraction and fixation, except for the graft and shaping of the interbody space. ACDF can also restore alignment by pulling the involved vertebral bodies toward the lordotic ventral plate. **Xu, et al., (13)** reported that C2–C7 lordosis decreased in the posterior group.

A study by **Audat, et al. (14)** showed that radiological bony fusion was evaluated using X-ray at all intervals of follow-up. CT-scan was used in the last two follow-up periods. The fusion rate of posterior surgery was 50% in most of the previous study **Mayer, et al., (15)**. In our study, we noticed fusion within 3 months of surgery in both groups. The fusion rate increased gradually after that in nearly equal rhythm in both the groups till 12th month.

Complications of anterior cervical surgery include dysphagia, recurrent laryngeal nerve palsy, vertebral artery injury, Horner syndrome, postoperative hematoma, esophageal injury, unintended dural tear, superficial wound infection, and hardware complications **Bilbao et.al (16)**. Some studies have shown that recurrent laryngeal nerve (RLN) palsy is underreported **Ebraheim et al.(17)**. Dysphonia and/or hoarseness are the most common clinical expression of unilateral vocal paralysis.

Conclusion

both methods anterior and posterior approach are effective in treatment of multiple degenerative cervical disc disease accompanied by cervical kyphosis but anterior approach is better concerning sagittal alignment, degree of correction, blood loss, hospital stay, clinical and functional improvement and lower rate of correction lossbut it carries a little bit higher rate of complications.

References:

1. Smith JS, Klineberg E, Shaffrey CI, Lafage V, Schwab FJ, Protopsaltis T, et al. Assessment of surgical treatment strategies for moderate to severe cervical spinal deformity reveals marked variation in approaches, osteotomies, and fusion levels. *J World neurosurgery* 2016;91:228-237 DOI:10.1016/j.wneu.2016.04.020.
2. Traynelis VC, Tan LA, Riew KD. Biomechanics, radiographic parameters, and classification of cervical spine deformity. *J Neurosurgery*. 2017;81(2):197-203 DOI:10.1093/neuros/nyx388.
3. Luo J, Cao K, Huang S, Li L, Yu T, Cao C, et al. Comparison of anterior approach versus posterior approach for the treatment of multilevel cervical spondylotic myelopathy. *EuropeanSpine Journal* 2015;24(8):1621-1630 DOI:10.1007/s00586-015-3911-4.
4. Tan LA, Riew KD, Traynelis VC. Cervical spine deformity—part 2: Management algorithm and anterior techniques. *J Neurosurgery*2017;81(4):561-567 DOI:10.1093/neuros/nyx388.

5. Tan LA, Riew KD, Traynelis VC. Cervical spine deformity—part 3: Posterior techniques, clinical outcome, and complications. *J Neurosurgery* 2017;81(6):893-898 DOI:10.1093/neuros/nyx477.
6. Nottmeier EW, Deen HG, Patel N, Birch BJCSS. Cervical kyphotic deformity correction using 360-degree reconstruction. 2009;22(6):385-391.
7. Al-Ryalat NT, Saleh SA, Mahafza WS, Samara OA, Ryalat AT, Al-Hadidy AM. Myelopathy associated with age-related cervical disc herniation: A retrospective review of magnetic resonance images. *Ann Saudi Med.* 2017;37(2):130-137. DOI: 10.5144/0256-4947.2017.130.
8. El-Ghandour NM, Soliman MA, Ezzat AA, Mohsen A, Zein-ElabedinMjjons. The safety and efficacy of anterior versus posterior decompression surgery in degenerative cervical myelopathy: A prospective randomized trial. *Journal of neurosurgery* 2020;33(3):288-296.
9. Kristof RA, Kiefer T, Thudium M, Ringel F, Stoffel M, Kovacs A, et al. Comparison of ventral corpectomy and plate-screw-instrumented fusion with dorsal laminectomy and rod-screw-instrumented fusion for treatment of at least two vertebral-level spondylotic cervical myelopathy. *European Spine Journal* 2009;18(12):1951-1956.
10. Zaveri GR, Jaiswal NP. A comparison of clinical and functional outcomes following anterior, posterior, and combined approaches for the management of cervical spondylotic myelopathy. *Indian journal of orthopaedics.* 2019;53(4):493-50110.4103/ortho.IJOrtho_8_16.
11. Noh SH, Kim KH, Park JY, Kuh SU, Chin DK, Kim KS, et al. Anterior cervical discectomy and fusion vs posterior laminoplasty for the treatment of myelopathy due to two-level localized ossification of the posterior longitudinal ligament. *Medicine* 2020;99(33) DOI:10.1097/2FMD.00000000000020955.
12. Shamji MF, Massicotte EM, Traynelis VC, Norvell DC, Hermsmeyer JT, Fehlings MG. Comparison of anterior surgical options for the treatment of multilevel cervical spondylotic myelopathy: A systematic review. *Spine.* 2013;38(22S):S195-S20910.1097/BRS.0b013e3182a7eb27.
13. Xu L, Sun H, Li Z, Liu X, Xu .Anterior cervical discectomy and fusion versus posterior laminoplasty for multilevel cervical myelopathy: A meta-analysis. *International Journal of Surgery* 2017;48:247-253. DOI:10.1016/j.ijsu.2017.06.030.
14. Audat ZA, Fawareh MD, Radydeh AM, Obeidat MM, Odat MA, Bashaireh KM, et al. Anterior versus posterior approach to treat cervical spondylotic myelopathy, clinical and radiological results with long period of follow-up. *J SAGE open medicine.* 2018;6:2050312118766199.
15. Mayer M, Meier O, Auffarth A, Koller. Cervical laminectomy and instrumented lateral mass fusion: Techniques, pearls and pitfalls. *European spine Journal* 2015;24(2):168-185. DOI:10.1007/s00586-013-2838-x.
16. Bilbao G, Duarte M, Aurrecoechea JJ, Pomposo I, Igartua A, Catalán G, et al. Surgical results and complications in a series of 71 consecutive cervical spondylotic corpectomies. *Acta Neurochir* 152, 1155-1163 (2010). DOI:10.1007/s00701-010-0660-3.
17. Ebraheim NA, Lu J, Yang H, Heck BE, Yeasting RAJS. Vulnerability of the sympathetic trunk during the anterior approach to the lower cervical spine. *Spine: July 1, 2000 - Volume 25 - Issue 13 - p 1603-1606.*